Pictorial Essay

Totally implantable chemoport device insertion technique

Harish K

[1]Professor and HOD, Department of Surgical Oncology, HCG MSR Cancer Center, M. S. Ramaiah Medical College, Bangalore 560054, INDIA.
Email: drkhari@yahoo.com

Abstract

Subcutaneous chemoport placement is a preferred long term venous access for cancer chemotherapy. These totally implantable devices are plastic or metallic with silicon membrane which facilitates repeated intermittent venous access. We describe the percutaneous subclavian access and port placement. The procedure involves seldinger technique of vein access, followed by vessel dilator and introducer sheath advancement over the guide wire. The catheter is then advanced into the sheath; tip placed at atrio-caval junction and the distal end is tunneled to reach the port pocket which is created. Distal end of catheter is then appropriately cut, and fixed to the port stem and secured with catheter lock. Port is then fixed to the fascia underneath and the wound is sutured. Positioning and patency are checked during and at the end of procedure.

Keywords: Chemoport, Catheter, Long term venous access.

***Address for Correspondence:**
Dr. Harish K., Professor and HOD, Department of Surgical Oncology, HCG MSR Cancer Center, M. S. Ramaiah Medical College, Bangalore 560054, INDIA.
Email: drkhari@yahoo.com

Received Date: 14/01/2015 Revised Date: 19/01/2015 Accepted Date: 24/01/2015

Access this article online	
Quick Response Code:	Website: www.medpulse.in
	DOI: 26 January 2015

INTRODUCTION

Establishing and maintaining medium to long term venous catheters is required for patients undergoing chemotherapy as they minimize the discomfort of frequent cannulation and related complications. Metallic or plastic casing port with silicon membrane is a long term venous access device used for administration of chemotherapy.[1] These are totally implantable vascular access devices for repeated intermittent vascular access. Although other veins including internal jugular and sometimes femoral are used, subclavian vein remains one of the most commonly used vessel for venous access. Ultrasound guided access reduces failure rate and insertion time for internal jugular access but because of the anatomy, such guided access to subclavian veins is more difficult and less reliable.[2] Both open access and seldinger techniques are described for vein access. However, percutaneous procedure is superior to open access in terms of theatre time, cosmetic result and local infective complications.[3-5] But there is a higher incidence of pneumothorax. The percutaneous subclavian venous access and port placement is one of the most popular approaches[1] and this work illustrates the procedure.

PRE-PROCEDURE PREPERATION

The procedure is discussed with the patient as it is performed under local anaesthesia. Pre procedure, patient is screened for anatomic or skeletal abnormalities and bleeding parameters. Right or left subclavian access depends on the surgeon's convenience. Sometimes, other factors dictate the side as in patients with breast cancer. In these patients, contra-lateral side is preferred as ipsilateral side could receive radiation. Universal precautions of sterility at surgery are maintained. Although there are arguments for blind placement,[6,7] it is safe to introduce and place the catheter under guidance.[8] Catheters have been placed at angiographic suites.[8] At our centre, all ports are placed under fluoroscopic guidance in the cardiac catheterization lab. The image quality is far superior and it has still and video capture facility. However, the procedure can also be done under conventional C-arm. The pre-sterilized package containing the port device is opened maintaining sterility. All components are checked; the catheter, the port and the introducer sheath are flushed with heparinized saline. All these are placed such that they are easily accessible when

How to site this article: Harish K. Totally implantable chemoport device insertion technique. *MedPulse – International Medical Journal* January 2015; 2(1): 34-39. http://www.medpulse.in (accessed 28 January 2015).

required during the procedure.[9] Wide area of skin is prepared with povidone iodine. The appropriate area on the right or left side is draped.

THE PROCEDURE

With patient lying supine, arms by the side and neck turned to opposite direction, local anaesthesia is infiltrated into skin and deeper structures below the clavicle in the deltopectoral groove.[10,11] The subclavian vein should be entered at the junction of outer and middle thirds of clavicle to avoid 'pinch off'.[12] Medial placement of catheter can lead to compression of the catheter between the first rib and clavicle. This can cause damage and even severance of the catheter which is called 'pinch off'. The introducer needle is inserted in the deltopectoral hollow 1cm inferior to the junction of middle and proximal third of the clavicle and aiming slightly cephalad. A 5 to 10 degree angle is maintained relative to the chest wall (Figs 1A, 1B, 1C). In case arterial blood is drawn, withdraw the needle immediately and apply pressure for a few minutes. It indicates that the puncture is too lateral as the vein is medial to the artery. Once the vein is accessed, remove the syringe, straighten "J" tip of the guide wire with tip straightener and insert the tapered end of tip straightener into the needle (Fig 2A). Advance the guide wire into the needle and into the great vessels (Figs 2B, 2C). Check the position of the guide wire (Fig 2D). Sometimes, the guide wire could be in the opposite subclavian or the internal jugular veins. In such a case, it should be withdrawn and directed to the superior vena cava. Make a small stab adjacent to the needle / guide wire (Fig 3A) and dilate the area to facilitate the introduction of the sheath and introducer later (Fig 3B). With guide wire in place, the port placement site is planned and local anaesthetic is injected along the line of incision and as a field block (Fig 4A). The site is usually situated 2-4 cms below the vein access site. The size of the incision is just adequate for placement of the port (Fig 4B). The port placement pocket is then created using electrocautery and blunt dissection in the subcutaneous plane (Figs 4C, 4D). The subcutaneous tissue should be neither too thin (in which case skin erosion of port could occur) nor should it be too thick (in which case port access becomes difficult). A trial placement of port is done to verify the size of pocket and relation to the incision. The port access site should not be very near the skin incision site. Hence the port should be placed in the pocket such that the vein access site should be at least 1-2cms below the skin incision. The vessel dilator and introducer sheath is then advanced over the guide wire (Figs 5A, 5B, 5C). After confirmation (Figs 6A, 6B), guide wire and dilator are withdrawn as a unit leaving the introducer sheath in place (Figs 7A, 7B). The sheath opening should be closed with finger to prevent air embolism; the patient may also be encouraged to perform valsalva maneuver. Catheter is then advanced into the sheath (Figs 8A, 8B, 8C, 8D) such that the tip is beyond the atria. It could even be advanced to the ventricle. Care should be taken to reposition at this stage if ectopics are noted. The two handles of peel-apart sheath are grasped and pulled outward and upward simultaneously to tear the sheath and remove it (Figs 9A, 9B). The catheter is then brought to the port pocket with the help of tunneler (Figs 10A, 10B, 10C). Once the catheter is completely brought into the port site wound, the catheter is cut proximal to the barb of the tunneler and the catheter lock is placed on the catheter. The catheter is then withdrawn gently such that the tip is at the superior venacaval – atrial junction [1, 13] (Fig 11A). The catheter is held beyond the catheter lock and then cut at right angles. This would usually be between 20cm and 25cm from the tip depending on the length of the vessels, the build and nutritional status of the patient. The catheter is then advanced over the port stem (Fig 11B) beyond the barb. The catheter lock is advanced over the catheter and port stem (Figs 12A, 12B). This secures the catheter to the port. Non coring needle is then used to flush the port and catheter (Figs 12C, 12D) with heparinized saline. Port is then fixed to the fascia underneath with needle in place - the in-situ technique.[14-16] The port pocket and the vein puncture wounds are then sutured or stapled (Figs 13A, 13B, 13C). The entire length of the port – catheter is then visualized by fluoroscopy (Fig 13D).

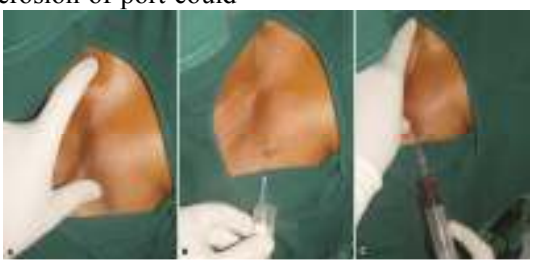

Figure 1: [A] showing thumb pressing the infraclavicular area in the deltopectoral groove, the index finger in the suprasternal notch; [B] showing infiltration of local anaesthesia in the deltopectoral groove; [C] shows syringe with the introducer needle has punctured the subclavian vein as evidenced by venous blood aspirated in the syringe.

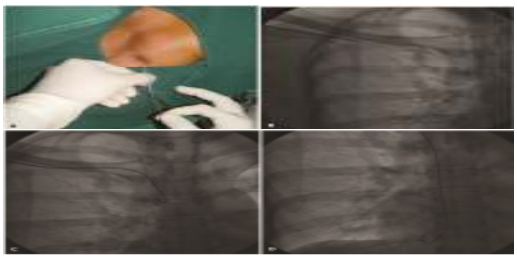

Figure 2: [A] guide wire being introduced into the introducer with the help of tip strainghtener. [B] guide wire in the introducer just short of the needle tip as seen on fluoroscopy. [C] guide wire in the superior venacava. [D] guide wire in tip in the right atrium.

Figure 3: [A] small skin stab just adjacent to the introducer needle. [B] small artery forceps used to slightly enlarge the stab all around the guide wire to facilitate the introduction of the introducer-sheath later

Figure 4: [A] infiltration of local anaesthesia before creation of port pocket. Note that this area is slightly away from the venous access site. [B] skin incision for creation of port pocket. [C] intial creation of port pocket. [D] the pocket for port placement is complete. [E] note that the size of skin incision (as well as the pocket) should be just adequate to accommodate the port.

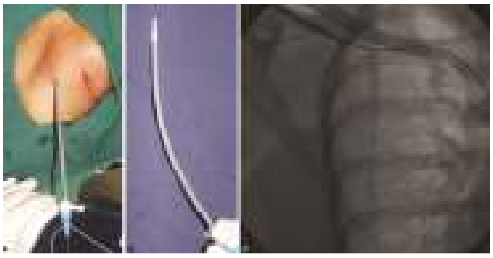

Figure 5: [A] the introducer peel away sheath and the vessel dilator are advanced over the guide wire as a single unit. [B] note that the dilator and introducer may be gently bent before advancement to suit the natural curvature of vessels. [C] the dilator and sheath are seen being advanced over the guide wire in the subclavian vessel under fluoroscopy

Figure 6: [A] the dilator sheath unit is advanced completely. [B] the corresponding fluoroscopy film showing the dilator and sheath over the guidewire.

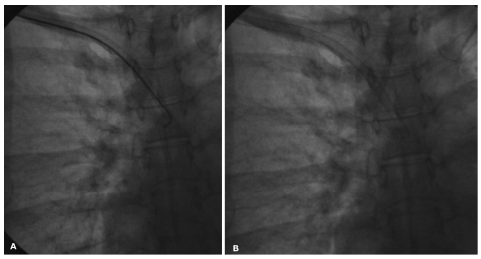

Figure 7: [A] Fluoroscopy showing the guidewire and dilator (not seen) being withdrawn together. [B] the introducer sheath alone is seen

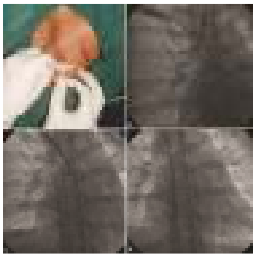

Figure 8: [A] catheter being advanced through the introducer sheath. [B] catheter is seen in the early part of the sheath – subclavian area. [C] catheter has crossed the tip of the introducer sheath. [D] catheter is in the right atrium

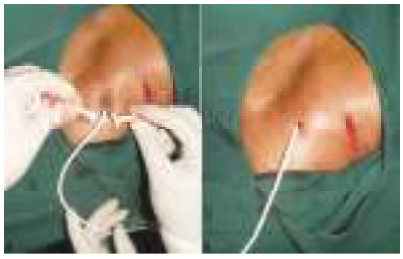

Figure 9: [A] introducer sheath being peeled away. [B] The catheter is in place. Sheath is completely removed.

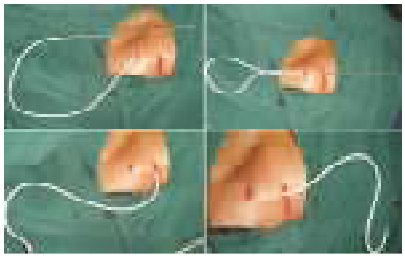

Figure 10: [A] The catheter is attached to the tunneler barb completely. [B] The tip of the tunneler is advanced from the venous access site to the port pocket site which is already created. [C] The catheter is gently pulled out of the port pocket wound. [D] The catheter lock is placed on the catheter.

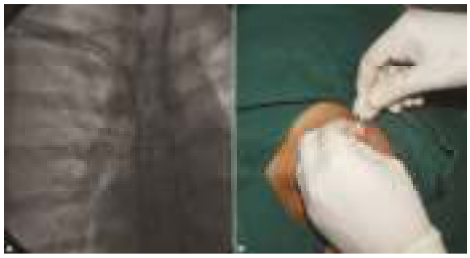

Figure 11: [A] The tip of the catheter is withdrawn appropriately so that the tip is placed at the superior vena cava and right atrial junction. [B] The end of the catheter which is cut at the port pocket site is then advanced over the port stem

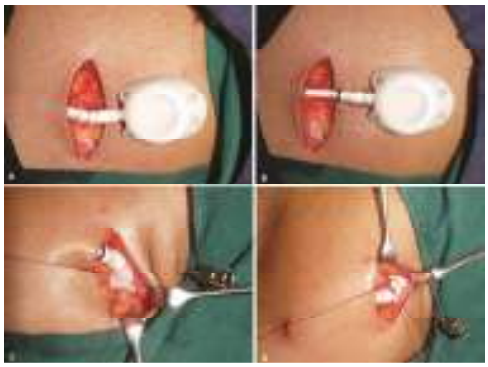

Figure 12: [A] The catheter is advanced over the port stem beyond the barb. [B] The catheter lock is advanced over the catheter and port stem to fix them securely. [C] and [D] port is fixed to underlying fascia. Note the Huber needle used to temporarily 'fix' the port till sutures are placed.

Figure 13: [A] The port placed in its position. The vein access and port pocket wounds are seen. [B] Both the wounds are sutured. [C] The port pocket wound is approximated with skin staples. Note the winged infusion set used to access and flush the port and the site of access is away from the main wound. [D] The chest radiogram at the end of the procedure showing the winged infusion set, the port and the catheter tip. Note that there are no kinks in the catheter.

CONCLUSION

Chemoports can be safely implanted under fluoroscopic guidance with seldinger technique. Precautions to ensure sterility are very important as a foreign body is implanted. Fluoroscopy ensures exact positioning of the catheter tip and absence of kinks. There is an initial learning curve for subclavian access. Use of ultrasound for facilitating subclavian vein access is not very useful because of local anatomy. It is important to ensure lateral entry into subclavian vein to avoid 'pinch off'. Tip positioning at atrio-caval junction ensures less chances of thrombosis and fibrin formation. The skin flap of the port pocket should be of adequate thickness to avoid erosion and facilitate easy palpation. Needle access to port should be at least 1 – 2 cms below the skin incision. The entire length of the catheter should not have any kinks.

REFERENCES

1. Gallieni M, Pittiruti M, Biffi R. Vascular access in oncology patients. CA Cancer J Clin. 2008; 58(6):323-346.
2. Randolph AG, Cook DJ, Gonzales CA, Pribble CG. Ultrasound guidance for placement of central venous catheters: a meta-analysis of the literature. Crit Care Med. 1996; 24(12):2053-2058.
3. McBride KD, Fisher R, Warnock N, Winfield DA, Reed MW, Gaines PA. A comparative analysis of radiological and surgical placement of central venous catheters. Cardiovasc Intervent Radiol. 1997; 20(1):17-22.
4. Adam A. Insertion of long term central venous catheters: time for a new look. BMJ. 1995; 311(7001):341-342.
5. Ahmed Z, Mohyuddin Z. Complications associated with different insertion techniques for Hickman catheters. Postgrad Med J. 1998; 74(868):104-107.
6. Kincaid EH, Davis PW, Chang MC, Fenstermaker JM, Pennell TC. "Blind" placement of long-term central venous access devices: report of 589 consecutive procedures. Am Surg. 1999; 65(6):520-523; discussion 523-524.

7. LaBella G, Kerlakian G, Muck P, Chung D, Vaughan A, Ritchison A. Port-A-Cath placement without the aid of fluoroscopy or localizing devices: a community hospital series. Cancer J. 2005;11(2):157-159.
8. Burnett AF, Lossef SV, Barth KH, *et al*. Insertion of Groshong central venous catheters utilizing fluoroscopic techniques. Gynecol Oncol. 1994; 52(1):69-73.
9. Gonda SJ, Li R. Principles of subcutaneous port placement. Tech Vasc Interv Radiol; 14(4):198-203.
10. Cantu-Martinez A, de-la-Garza-Castro O, Espinosa-Galindo AM, *et al*. Modification of the technique for subclavian-vein catheterization. Rev Invest Clin. 2009; 61(6):476-481.
11. Hu B, Hu M, Wang Y, Wang DW. Simplifying subclavian vein cannulation using innovative landmarks: a radiologic, anatomic, and clinical study. Adv Emerg Nurs J. 2012; 34(2):170-176.
12. Jordan K, Behlendorf T, Surov A, Kegel T, Maher G, Wolf HH. Venous access ports: frequency and management of complications in oncology patients. Onkologie. 2008; 31(7):404-410.
13. Schwarz RE, Coit DG, Groeger JS. Transcutaneously tunneled central venous lines in cancer patients: an analysis of device-related morbidity factors based on prospective data collection. Ann Surg Oncol. 2000; 7(6):441-449.
14. Whitman ED. Complications associated with the use of central venous access devices. Curr Probl Surg. 1996; 33(4):309-378.
15. Ignatov A, Hoffman O, Smith B, *et al*. An 11-year retrospective study of totally implanted central venous access ports: complications and patient satisfaction. Eur J Surg Oncol. 2009; 35(3):241-246.
16. Harish K, Madhu YC. Chemoport anchoring - the in situ technique. Surgical Techniques Development. 2011; 1:e9.

Source of Support: None Declared
Conflict of Interest: None Declared