Original Research Article

# Surgical management of a case of a large recurrent sebaceous carcinoma of the lower eyelid

V Kohli[1*], S T Mittal[2], S Kumar[3]

[1]Associate Professor, [2]Senior Resident, [3]Professor, Department of Ophthalmology, Post Graduate institute of Medical Sciences and Research, Basaidarapur, Ring Road, New Delhi – 110015.
**Email:** drshilpataneja23@gmail.com, dr.vkohli@gmail.com, sandeep_65@yahoo.com

## Abstract

**Background:** Sebaceous carcinoma is an eyelid malignancy commonly seen in Asian population that originates from the Meibomian glands, glands of Zeis or from the sebaceous glands in the caruncle. It is sometimes mistaken for a chalazion or a benign lid mass or a blepharoconjunctivitis and hence not managed well. **Case:** We present one such case, a 55-year-old woman who presented with a recurrent sebaceous carcinoma in the lower lid that progressed rapidly to attain a large size of 22mm X 18mm X15mm. The tumour was excised with wide margins of 6mm and under frozen section control. The lower lid was then reconstructed with the help of a large Hughes tarsoconjunctival flap from the upper lid for forming the posterior lamella and a cheek rotation flap for constructing the anterior lamella. After three weeks, the conjunctival pedicle was severed and the lids could be opened. **Observations:** The reconstructed lower lid was well apposed to the globe and was functionally and cosmetically satisfactory. The patient has been on a regular follow up for the past 15 months and has not had a local recurrence, regional lymph node involvement or a systemic metastasis as yet. **Conclusions:** Excision of an eyelid malignancy should be done with wide margins and under frozen section analysis and lid reconstruction should be done only when the margins are declared to be tumour free. Hughes tarsoconjunctival flap combined with a cheek rotation flap provide a good outcome in patients with large recurrent sebaceous carcinoma of the lower lid.
**Keywords:** eyelid reconstruction, sebaceous gland neoplasm.

[*]**Address for Correspondence:**
Dr. V Kohli, Associate Professor, Department of Ophthalmology, Post Graduate institute of Medical Sciences and Research, Basaidarapur, Ring Road, New Delhi – 110015.
**Email:** dr.vkohli@gmail.com
Received Date: 04/07/2015 Revised Date: 18/08/2015 Accepted Date: 23/09/2015

| Access this article online | |
|---|---|
| Quick Response Code: | Website: www.medpulse.in |
|  | DOI: 18 October 2015 |

## INTRODUCTION

Sebaceous carcinoma in the periocular region is a malignant tumour that arises from the sebaceous glands in the tarsal plates (meibomian glands) or the sebaceous glands associated with the cilia (glands of Zeis) or the sebaceous glands located in the caruncle or the eyebrow region. Sebaceouscarcinoma comprises about 8-37% of all eyelid malignancies in Asia[1-4] but only 1-7% of all eyelid malignancies in the West.[5-8]It is important to identify this malignancy early and manage it well as it has a high incidence to spread and may lead to orbital invasion, regional lymphadenopathy and systemic metastases. In the initial stages, it may be confused with a chalazionor a blepharocojunctivitis but its yellowish colour, distortion of eyelid margin architecture and loss of eyelashes should arouse suspicion as they point towards the diagnosis of a sebaceous carcinoma.

If this tumour is not managed well in its early stages, it may attain a large size and may present a formidable surgical challenge for proper management. We hereby present one such recurrent case.

How to site this article: V Kohli, S T Mittal, S Kumar. Surgical management of a case of a large recurrent sebaceous carcinoma of the lower eyelid. *MedPulse – International Medical Journal* October 2015; 2(10): 705-709. http://www.medpulse.in (accessed 22 October 2015).

## CASE REPORT

A 55-year-old farmer woman presented with a painless mass in her left lower eyelid that had been rapidly growing for the last 6 months. She gave a history of the removal of a small lesion from the same site 12 months back but could not provide any further details nor any records.

The lower lid mass was 22 mm X 18 mm X 15 mm in size, yellowish pink, firm, with an irregular surface and some telangiectatic vessels. The bulbar and superior palpebral conjunctiva appeared to be uninvolved. There was no proptosis or dystopia or strabismus. There was no preauricular or cervical lymphadenopathy nor any evidence of systemic metastasis. Contrast enhanced CT scanning revealed a heterogeneously enhancing mass lesion involving the lower lid but with no orbital extension.

Figure 1

Figure 2

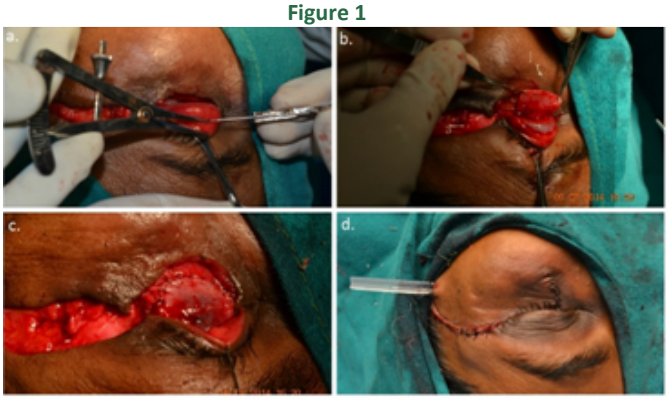

Figure 3

Figure 4

**Figure 1:** a,b.Preoperative photograph showing a yellowish- pink mass in the left lower eyelid with an irregular surface. c,d.Contrast enhanced CT imaging showing a heterogeneously enhancing mass lesion in the lower eyelid.

The mass was excised with 6 mm wide margins and sent for frozen section analysis. An extra thin layer of tissue was excised from the inferior aspect and sent separately for frozen section analysis. Conjunctival map biopsies were also takenand sent separately for histopathological examination.[9]

**Figure 2:** Peroperative photographs depicting a. The excised tumour with 6 mm margins with the margins marked by sutures. b.Lid defect after tumour excision. c. Skin marking for the cheek rotation flap. d. The undermined cheek rotation flap.

**Figure 3:** Peroperative photographs depicting a. Incising the tarsus for obtaining a Hughes tarsoconjunctival graft. b.The Hughes tarsoconjunctival graft of appropriate width. c.Hughes tarsoconjunctival graft sutured into the defect . d. The patient after completion of the first stage of surgery with theHughes tarsoconjunctival graft and the cheek rotation flap sutured into place.

**Figure 4(a,b):** The patient after 2 weeks of the first surgery showing the intact conjunctival pedicle. c. Peroperative photograph showing the eye after severing the conjunctival pedicle. d. The patient 20 days after severing of the conjunctival pedicle showing a good cosmetic result.

When the frozen section analysis indicated that all the margins of the excised mass was free of tumour, lid reconstruction was carried out. The anterior lamella was constructed via a cheek rotation flap.The posterior lamella was reconstructed using the tarsoconjunctiva from the upper lid via a Hughes flap. The inner surface of the cheek flap was anchored to the lateral orbital periosteum with the help of a double armed 5-0 polypropylene suture to anchor the flap properly and prevents its sagging. The histopathological analysis of the

conjunctival map biopsies did not reveal any pagetoid spread of tumour. Three weeks later the Hughes flap was excised.The reconstructed lid is positioned well and is functionally and cosmetically satisfactory. The patient has had a follow up of 15 months by now and has not had a recurrence nor any cervical lymphadenopathy.

## DISCUSSION

Sebaceous carcinoma is a carcinoma that arises in the eyelids from the Meibomian glands, glands of Zeis or in the sebaceous glands located in the caruncle or the brow region or very rarely as a primary tumour in the lacrimal gland. Approximately 75%of these lesions are seen in the upper lid, 22% in the lower lid, 2% in the caruncle and 2% in the eyebrow region.[2,5]It is presumably seen more in the upper lid than the lower lid as the number of Meibomian glands is more in the upper lid than in the lower lid. Rarely, it may be multicentric.

In Asia, both basal cell carcinoma and sebaceous carcinoma have a comparable frequency of about 30% [1-4]but in the West, basal cell carcinomas comprise about 90% of all eyelid malignancies, sebaceous carcinomas about 5-6%, squamous cell carcinomas 4% and melanomas about 1%.[5-8] Sebaceous carcinoma is usually seen in the older age group with the mean age ranging from 55-73 years and most studies state that it is more common in women (57-77%) than in men but some studies indicate the opposite.[1-8] It may be associated with previous irradiation to the orbital region, immunosuppressed patients with HIV disease or in association with Muir- Torre syndrome.[5] Muir Torre syndrome is an autosomal dominant condition characterised by skin lesions such as sebaceous epitheliomas, sebaceous carcinomas and visceral gastrointestinal malignancies.[10]

Sebaceous carcinoma has a propensity to spread to the orbital tissues and to the draining lymph nodes and can even lead to systemic metastases to the liver, lungs or brain. It also shows a characteristic pagetoid spread to the adjacent conjunctival and epidermal epithelium. It may then appear clinically as a blepharoconjunctivitis, papillary conjunctivitis, superior limbic conjunctivitis or even a corneal pannus.[5]Its unilaterality, chronicity, presence in older individuals, absence of responsiveness to usual medications and associated lid changes should arouse suspicion.

In the early stages, it may be mistaken for a chalazion. But when it is present in an older patient, or if it is associated with thickening and rounding of the lid margin or loss of Meibomian duct orifices and cilia, then a high index of suspicion should be maintained. All suspicious lid masses should be evaluated histopathologically by a well trained pathologist so that the diagnosis is not missed.

**Histopathology**

Histopathologically, these tumours consist of irregularly shaped, variably sized lobules of cells with foamy, vacuolated cytoplasm and large hyperchromatic nuclei with prominent nucleoli and increased mitotic activity. It is commonly found in four different patterns – lobular, comedocarcinoma, papillary and mixed.[11] It is also classified into well- differentiated, moderately differentiated and poorly differentiated carcinoma.It is also important to look for pagetoid spread and lymphatic and vascular invasion by malignant cells. Pagetoid spread into the surrounding conjunctival and epidermal epithelium is seen as groups of malignant foamy cells scattered in the normal epithelium and warrants specific management. Presence of lymphatic and vascular invasion by malignant cells indicates a higher chance of metastases and such patients need to be monitored carefully.

Usually the histopathological diagnosis is made by standard histopathological examination techniques supplemented with fat stains such as Oil Red O stain but at times, the tumour may be very poorly differentiated and immunohistochemical stains may be required. EMA (Epithelial membrane antigen) positivity is seen in sebaceous carcinoma and squamous cell carcinoma but not in basal cell carcinoma. Cam 5.2 positivity is seen in sebaceous carcinoma but not in basal cell carcinoma. Adipophilin and perilipin positivity is seen in sebaceous carcinoma.[11]

**Principles of Management**

The mainstay of treatment of sebaceous carcinoma is complete surgical removal of the tumour with wide margins followed by careful reconstruction of the lid. FNAB (fine needle aspiration biopsy) or incision biopsy may be done to confirm the diagnosis before taking upthe patient for a wide surgical excision but the time gap between the two should be as short as possible. The tumour should be excised with 5-6 mm of normal margins and the margins subjected to frozen section analysis. Only when the frozen section analysis showsthat the margins of the excised tissue are free from tumour should the lid be reconstructed. If any of the margins are not tumour free, further excision of the involved margin is done and the excised tissue again sent for frozen section analysis. Excisions with 5mm or more than 5 mm margins report a lower recurrence rate or subsequent lymphadenopathy than excisions with margins less than 5mm.[1,3,5] Hence it is advisable to take a margin of at least 5 mm to decrease the rate of recurrence or lymphadenopathy. Moh's micrographic surgery is not a very good option for

sebaceous carcinoma due to this carcinoma's tendency for pagetoid spread though Spencer et al reported good results using this technique.[12]

If the lesion is very large and difficult surgery is anticipated, neoadjuvant chemotherapy may be given with carboplatin and 5-Flourouracil to reduce the size of the tumour and make it more surgically amenable. Kaliki et al gave 3-4 cycles of this chemotherapy to 10 patients of eyelid sebaceous carcinoma with a mean basal diameter of 36 mm and orbital extension in 9 patients.[13] They found a mean size reduction of 74%. No major side effects of chemotherapy were noted. Five patients were then taken up for surgical excision and 2 patients for eyelid sparing exenteration. None of these 7 patients developed a recurrence after a mean follow up of 18 months. Murthy et al used this chemotherapy in a patient with recurrent sebaceous carcinoma with orbital extension and regional lymph node involvement.[14]After 3 cycles of chemotherapy, the patient underwent lid sparing exenteration which was then followed by 3 more cycles of chemotherapy and radiotherapy to the lymphnodes. The patient did not need to undergo radical neck dissection and had remained cancer-free for at least 26 months.

If the patient seems to have a pagetoidextension into the conjunctiva, the patient is given 3-4 cycles of topical mitomycin C therapy after confirmation of the map biopsies by histopathological analysis.[5] One cycle of this therapy consists of topical application of Mitomycin C drops (0.02% to 0.04%) 4 times a day for 1-2 weeks followed by a gap of 1-2 weeks. Usually 3-4 cycles are required for the disappearance of the pagetoid extension. If there is only a localised conjunctival involvement, double freeze cryotherapy may be applied to the involved conjunctiva.

Exenteration is required in patients with intraocular extension and orbital extension. If possible, a skin sparing exenteration should be done so that the orbit may be lined with the remaining skin and the orbit is not left bare. This helps in early healing of the orbit and early fitting of orbital prosthesis. Even in cases with orbital extension, the skin, except for the skin near the lidmargin, may be uninvolved by the tumour as sebaceous carcinoma involves mainly the posterior lamella. In such cases, eyelid sparing exenteration may be feasible in which the skin near the lid margin is sacrificed with the tumour but the remaining uninvolved skin is preserved and used to line the orbit.

There is a limited role of irradiation in the treatment of sebaceous carcinoma as this tumour is not very radiosensitive. It is useful for treating lymph node metastases, orbital recurrence following exenteration and lid sebaceous carcinomas in patients who are too debilitated to undergo surgery or who are unwilling for surgery. Yen et al reported success with more than 55 Cgy of megavoltage X-ray irradiation.

Systemic chemotherapy is useful in treating patients with systemic metastases and as neoadjuvant therapy as described earlier.

## Principles of surgical reconstruction of the lower lid

Reconstruction of the lower lid is planned according to the size of the defect, the location of the defect and the laxity of the surrounding skin. If the defect is less than one third of the lid and the tissues are lax, the cut edges are brought close together with the help of two forceps and if they can be opposed with a minimum amount of tension, then a direct multi-layered closure is done with careful apposition of the tarsal plates so that there is no lid notching. Lateral cantholysis and freeing of orbital septum is also done to help oppose the tissues without tension. If the defect is largerand about half the lid length, a Tenzel's semicircular flap may be used to repair the defect. A semicircular flap of skin and orbicularis is mobilized from the lateral canthal area and pulled medially to reconstruct the lid. This flap should not extend at this depth laterally beyond the lateral end of the eyebrow so as to not damage the facial nerve.

If the defect is more than half the lid length, the reconstruction becomes more challenging. The posterior lamella is reconstructed by either a tarsoconjunctival flap (Hughes technique) or a free tarsoconjunctival graft or a nasal septal cartilage with nasal mucosa or a hard palate graft or a buccal mucosal graft. The anterior lamella is constructed by mobilization of surrounding skin or by rotation flap, pedicle flap or a free skin graft. Flaps heal better and give better results than free grafts as they have an intact blood supply but free grafts are initially devoid of a blood supply and are dependent on the surrounding vascularized tissues for their survival. Hence both the anterior and posterior lamellae cannot be free grafts but either of them can be a graft provided the other lamella is a flap with a good blood supply.

Hughes tarcoconjunctival flap is very useful for lower lid defects as it provides a vertical lift to the reconstructed lower lid and prevents its sagging down. A horizontal incision is made in the superior tarsus 4 mm above the lid margin. A tarsoconjunctival flap of suitable horizontal length is raised after freeing it from the lid retractors. This flap is then sutured into the lower lid defect. The skin cheek rotation flap is then rotated and sutured to the medial edge of the defect and to the tarsoconjunctival flap. After three weeks, the conjunctival pedicle is cut and the upper and lower lids separated. If there is upper lid retraction, the upper lid retractors are freed to get the appropriate lid position. Thus, this combination of a

cheek rotation skin flap and a tarsoconjunctival flap gives an excellent functional and cosmetic result.

## CONCLUSION

Sebaceous carcinoma is a common eyelid tumour in Asia with a high propensity for local and systemic spread. Careful clinical examination, keeping a high index of suspicion and proper surgical management can help in providing a good outcome to these patients. Systemic chemotherapy with carboplatin and 5-flourouracil should be used in patients with very large surgically inoperable tumours and in patients with regional lymph node involvement and systemic metastases. Surgery should be done with wide margins of more than 5mm and frozen section control and lid reconstruction should be carried out carefully only after the margins have been declared tumour free.

## REFERENCES


1. Jahagirdar SS, Thakre TP, Kale SM, Kulkarni H, Mamtani M. A clinicopathological study of eyelid malignancies from central India. Indian J Ophthalmol2007;55:109-12.
2. Wang CJ, Zhang HN, Wu H, Shi X, Xie JJ, He JJ, Kook KH, Lee SY, Ye J.Clinicopathologic features and prognostic factors of malignant eyelid tumors. Int J Ophthalmol. 2013 Aug 18;6(4):442-7.
3. Domingo RE, Manganip LE, Castro RM. Tumors of the eye and ocular adnexa at the Philippine Eye Research Institute: a 10-year review. ClinOphthalmol. 2015 Jul 9;9:1239-47.
4. Yueh-Ju Tsai, Shu-Ya Wu, Hsuan-Ying Huang, David Hui-Kang Ma, Nan-Kai Wang, Ching-Hsi Hsiao, Ching-Yi Cheng, Lung-Kun Yeh.Expression of retinoic acid-binding proteins and retinoic acid receptors in sebaceous cell carcinoma of the eyelids. BMC Ophthalmol. 2015; 15:142.
5. Shields JA, Demirci H, Marr BP. Sebaceous carcinoma of the ocular region. SurvOphthalmol. 2005;50:103-122.
6. Deprez M, Uffer S. Clinicopathological features of eyelid skin tumors. A retrospective study of 5504 cases and review of literature. Am J Dermatopathol. 2009;31:256-262.
7. Kass LG, Hornblass A. Sebaceous carcinoma of the ocular adnexa. SurvOphthalmol. 1989; 33: 477–490.
8. Dasgupta T, Wilson LD, Yu JB. A retrospective reviewof 1349 cases of sebaceous carcinoma. Cancer. 2009;11:158-165.
9. Putterman AM. Conjunctival map biopsy to determine pagetoid spread. Am J Ophthalmol. 1986;102:87Y90.
10. Sara C Shalin, Stephen Lyle, Eduardo Calonje, Alexander J F Lazar.Sebaceous neoplasia and the Muir–Torre syndrome: important connections with clinical implications. Histopathology. 2010 January; 56(1): 133–147.
11. Mulay K, Aggarwal E, White VA. Periocular sebaceous gland carcinoma: a comprehensive review. Saudi J Ophthalmol. 2013;27: 159-165.
12. Spencer JM, Nossa R, Tse DT, Sequeira M. Sebaceous carcinoma of the eyelid treated with Mohs micrographic surgery. J Am AcadDermatol. 2001;44:1004–1009.
13. Kaliki S, Ayyar A, Nair AG, Mishra DK, Reddy VA, Naik MN. Neoadjuvant Systemic Chemotherapy in the Management of Extensive Eyelid Sebaceous Gland Carcinoma: A study of 10 Cases. OphthalPlastReconstr Surg. 2015 Feb 11.
14. Murthy R, Honavar SG, Burman S, Vemuganti GK, Naik MN, Reddy VA.Neoadjuvant chemotherapy in the management of sebaceous gland carcinoma of the eyelid with regional lymph node metastasis.OphthalPlastReconstr Surg. 2005 Jul;21(4):307-9.
15. Yen MT1, Tse DT, Wu X, Wolfson AH. Radiation therapy for local control of eyelid sebaceous cell carcinoma: report of two cases and review of the literature. BMC Ophthalmol. 2015; 15: 142.


Source of Support: None Declared
Conflict of Interest: None Declared