Original Article

Management of complex and complicated orthopedic conditions of leg with Taylor spatial frame

Bhushan Patil[1*], Sandeep Shrivastava[2], Sanjay V. Deshpande[3], Sparsh Naik[4], Moin Mehmood[5], Hitendra Wamborikar[6]

[1,5,6,]Jr. Resident, [2]Professor and Dean, [3]Professor and HOD, [4]Sr.Resident, Department of Orthopaedics, AVBRH, Wardha, Maharashtra, INDIA.

Email: bhushann1001@gmail.com

Abstract

Aim: To study the role of Taylor spatial frame in the treatment of complex and complicated tibial disorders. **Material and methods:** 13 patients having complex deformity (3 Dimension) of Tibia including fractures with complex configurations and patients having union related complications after tibia fracture such as infected nonunion, non-union and malunion using TSF were treated with TSF. Radiographic and functional scoring was done using ASAMI scoring system. **Result:** The mean age of the patients was 35.15 years. The mean duration of deformity correction was 2.38 weeks. The mean Distraction – Consolidation time was 14.69 weeks. The mean duration of external fixator was 17.8 weeks. Bone scoring using ASAMI criteria revealed 8 excellent, 3 good, 1 fair, and 1 poor result. Functional assessment using ASAMI criteria graded 7 patients as excellent, 4 as good, 1 as fair and 1 as poor. **Conclusion:** In combination with computer software, by adjusting only the strut lengths on a simple frame, it allows multiplanar corrections also of residual deformities without complex modifications of the device.

Keywords: Taylor spatial frame.

[*]**Address for Correspondence:**
Dr. Bhushan Patil, Jr. Resident, Department of Orthopaedics, AVBRH, Wardha, Maharashtra, INDIA.
Email: bhushann1001@gmail.com

Received Date: 14/10/2016 Revised Date: 10/11/2016 Accepted Date: 03/12/2016

Access this article online	
Quick Response Code:	Website: www.medpulse.in
	DOI: 05 December 2016

INTRODUCTION

With the development of Principles of Distraction osteogenesis and Ring Fixators by Ilizarov, a revolution was created by redefining the role of External Fixators in the management of Complex deformities including bone - loss in extreme situation.[1] The ring fixator has been instrumental in the management of the complex disorders of limbs including management of compound fracture, since almost 75 years.[1,2] But as the utility and application of ring fixators grew, newer problems crept in including the complexity in managing the fixator itself, such situations as 3 dimensional corrections, wherein either it was required to change the configurations as per the corrections got achieved. At times it was too cumbersome too handle. External fixation has traditionally been favored in deformities with soft-tissue problems, those with unstable fracture configurations and periarticular fractures.[3-11] The Taylor spatial frame (TSF) is a more recent circular fixator that corrects multiplanar limb deformities using computer software program. The Taylor spatial frame (TSF) (Smith and Nephew, Memphis, TN, USA) was developed by Charles Taylor in 1994. The TSF was a pioneer attempt to blend the computer technology in the corrections of deformities. These external fixators are devices of future to overcome the extreme problems of managing cases such as compound fractures with bone loss, Bone transportation needs, multidimensional deformities of long bones etc. Hence this study investigates the role of such next generation software

How to site this article: Bhushan Patil *et al*. Management of complex and complicated orthopedic conditions of leg with Taylor spatial frame. *MedPulse – International Medical Journal.* December 2016; 3(12): 1015-1019. http://www.medpulse.in (accessed 08 December 2016).

based and computer navigated external fixator in the treatment of complex and complicated tibial disorders.

MATERIAL AND METHODS

Between 2014 to 2016, we treated 13 patients having complex deformity (3 Dimension) of Tibia including fractures with complex configurations and patients having union related complications after tibia fracture such as infected nonunion, non-union and malunion using TSF. Patients with multiple bone deformities in the same lower limb such as femur involvement, Patients with contractures of knee/ ankle joint/ foot joint and Patients with bone defects and bone loss of more than 2cms, in which primary aim of treatment was lengthening were excluded from the study. There were 11 (84.61%) male and 2 (15.39%) female patients and their mean age was 35.15 years. There were 10 (76.92%) patients of fracture, 2 (15.38%) patients of malunion and 1 (7.69%) patient of non-union. Each patient underwent detailed pre-operative assessment in the form of clinical evaluation- Side affected, Level of deformity, Fracture type, Distal arterial pulsation, Rotational deformity and Radiological evaluation- Mechanical axis radiogram along with anterior-posterior and lateral X-ray of every patient were done for calculation of the deformity. Mechanical axis x-ray included both lower limbs from hip to ankle with patient in standing position, both the limbs were kept parallel with both knee in extension and patella facing forward. 51 inches cassette was used to obtain mechanical axis x-ray which was long enough to include the hips, knees, and ankles. The radiography tube was positioned 10ft (305cm) away to it. In patients with torsional deformity of tibia, the same position with patella forward was maintained. Deformity correction with TSF was un-hinge concept and depended upon the accuracy of calculating the deformity parameters on radiogram. Corticotomy was done in 5 cases. Corticotomy was done nearest as possible to the apex. Corticotomy was done either classically or with gigli saw. Distraction was as per the schedule prepared pre-operatively for TSF. Following parameters values were observed post operatively and at subsequent follow ups -Associated lengthening, Duration of external fixator, Duration of deformity correction, Distraction consolidation time, Complications – pin track infection, wire breakage, refracture, pin loosening, poor quality regenerate, pulmonary embolism, persistent pin site infection, knee flexion deformity.Radiographic and functional scoring was done using ASAMI scoring system. Follow ups were taken at 1st, 3rd, 6th and 9th months. The external fixator were removed once three cortices consolidation at the regenerate site and union at the fracture site was noted.Further after removal and healing of pin site tract a Patellar Tendon Bearing (PTB) cast for 4 to 6 weeks was given to all the patients.After the cast removal, all the patients were put to good physiotherapy to achieve good functional stability. Statistical Analysis was done by using descriptive and inferential statistics using Chi square test and software used in the analysis were SPSS version 17.0 and GraphPad Prism version 5.0 and $p < 0.05$ was considered as level of significance.

RESULT

3 patients had undergone previous surgeries, out of which 2 patients underwent one surgery and 1 patient underwent two surgeries. 9 patients had the deformity on the right side while 4 patients had the deformity on the left side. 3 patients had deformity in proximal 3rd tibia, 6 patients had deformity in middle 3rd tibia and 4 patients had deformity in distal 3rd tibia. Varus deformity was seen in 9 (69.23%) patients.Valgus deformity was seen in 4 (30.76%) patients. Anterior angulation was present in 6 (46.15%) patients. Posterior angulation was present in 7 (53.84%) patients. Internal rotation deformity was present in 9 (69.23%) patients and external rotation deformity was present in 4 (30.76%) patients. The mean MAD pre -correction was 12.8 whereas post -correction was 6.9, mean MPTA pre -correction was 92.7 whereas post-correction was 85.4, mean PPTA pre correction was 78.5 whereas post -correction was 81.5, mean ADTA pre-correction was 83.5 whereas post- correction was 80.7, mean LDTA pre -correction was 84.67 and post-correction was 89.30 in patients with proximal 3rd shaft tibial deformity. Mean MAD pre -correction was 9.7 whereas post -correction was 6.9, mean MPTA pre -correction was 90.5 whereas post- correction was 86.0, mean PPTA pre correction was 51.8 whereas post -correction was 81.2, mean ADTA pre- correction was 78.9 whereas post- correction was 80.5, mean LDTA pre -correction was 86.92 and post- correction was 88.72 in patients with middle 3rd shaft tibial deformity. Mean MAD pre -correction was 6.9 whereas post -correction was 7.4, mean MPTA pre -correction was 88.6 whereas post- correction was 88.1, mean PPTA pre correction was 79.6 whereas post -correction was 80.4, mean ADTA pre-correction was 81.7 whereas post- correction was 79.7, mean LDTA pre -correction was 87.78 and post-correction was 89.44 in patients with distal 3rd shaft tibial deformity.Corticotomy was done in 2 patients at proximal 3rd shaft tibia and middle 3rd shaft tibia each and in 1 patient at distal 3rd shaft tibia. The mean duration of deformity correction was 2.38 weeks. Associated Lengthening was 6.97 mm. The mean Distraction – Consolidation time was 14.69 weeks. The mean duration of external fixator was 17.8 weeks. Complications like Deep vein thrombosis was sen in 1 patient,persistent pin

site infection in 2 patients and knee flexion deformity in 1 patient. No residual deformity was observed in 8 patients(61.5%). Residual deformity of ≤5 degree was observed in 1 patient(7.7%), 6degree - 10 degree in 1 patient(7.7%),>10 degree in 3 patients(23.1%) out of total 13 patients. Bone scoring using ASAMI criteria revealed 8 excellent, 3 good, 1 fair, and 1 poor result. Functional assessment using ASAMI criteria graded 7 patients as excellent, 4 as good, 1 as fair and 1 as poor.

Table 1: ASAMI scoring system

Radiographic scoring - Bone Results	
Excellent	Union, no infection, deformity <7º, limb length discrepancy <2.5 cm
Good	Union + any 2 of the following: absence of infection, <7º deformity and limb length discrepancy <2.5 cm
Fair	Union + only one of the following: absence of infection, <7º deformity and limb length discrepancy <2.5 cm
Poor	Non-union/re-fracture/union + infection + deformity >7º + limb length discrepancy >2.5 cm
Functional results	
Excellent	Active, no limp, minimum stiffness (loss of <15 knee extension/<15 ankle dorsiflexion), no reflex sympathetic dystrophy (RDS), insignificant pain
Good	Active with 1 or 2 of the following: limp, stiffness, RSD, significant pain
Fair	Active with 3 or all of the following: limp, stiffness, RSD, significant pain
Poor	Inactive (unemployment or inability to return to daily activities because of injury)
Failure	Amputation

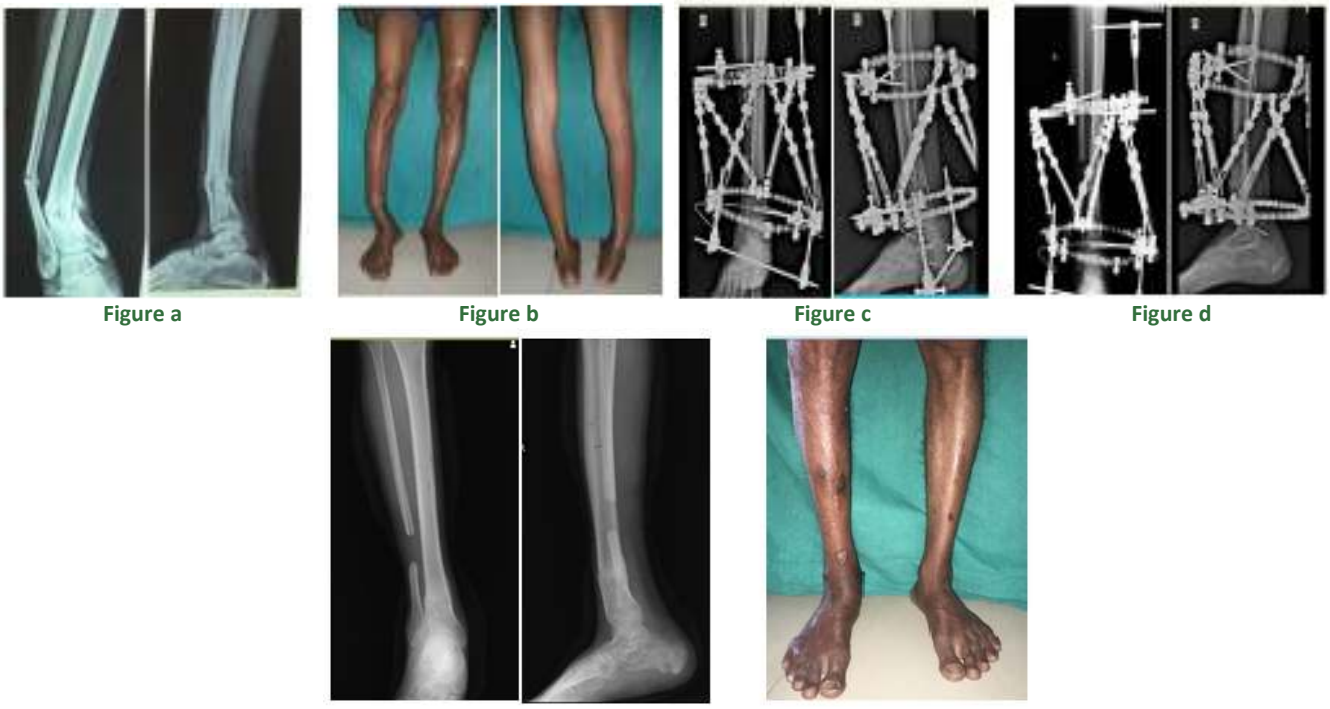

Figure 1: Case 1 managed with TSF
a): Pre-operative X-ray showing deformity of distal tibia; **b):** Clinical picture of deformity at presentation; **c):** Post-correction x-ray after 2 weeks; **d):** X-ray at 2nd follow –up; **e):** X-xay after removal of TSF; **f):** Clinical picture after complete treatment

DISCUSSION

We have in our study critically appraised the outcome of TSF treatment as per the level of deformity of tibia that is proximal 3rd, middle 3rd, and lower 3rd. This has not been done by any studies in the recent literature. This could be due to fact that we were working with limited inventory of TSF, hence the versatility of its application was limited in our hands. Specifically in terms of length of struts, we have mostly worked with medium struts, hence had a perception that, perhaps we may not be able to centralize different level of deformities in all cases. In our study, the pre operative and post operative mean MAD was 9.8 and 7.06 respectively, whereas in the study done by Ganger *et al*[12] the mean pre-operative MAD was 36.8 ± 18.3 and post-operative MAD was 7.2 ± 5.2. The significant difference in pre operative MAD can be attributed to

more number of acute injuries in our study than congenital or chronic deformities as seen in the study done by Ganger *et al* [12]. The mean pre-operative MPTA was 92.4 ± 1.5 and post-operative MPTA was 88.6 ± 1.5. The mean pre-operative LDTA was 101 ± 13.1 and post-operative LDTA was 90.3 ± 2.9 for all level of tibia deformities. In our study the mean associated lengthening was 6.97mm which was not significant. It is associated with deformity correction and is not targeted for correction of any limb length discrepancy hence it is not significant. The mean duration of deformity correction was 2.38 weeks. TSF software has provision to set the duration of deformity correction as required and TSF enables precise simultaneous multiplaner deformity correction. This reduces the duration for the correction of deformity. In our study along with the deformities patients we have included patients with acute fractures which have less severity of deformity; hence duration of correction was less as compared to Dammerer *et al*[13] study which had mean duration of deformity correction was 4.28 weeks with TSF.The mean distraction – consolidation time in our study was 14.69 weeks (98 days). The Distraction consolidation time in study done by Dammerer *et al*[13] was 148 days. As the patients with bone loss or bone defect more than 2 cm were excluded from our study, mean distraction–consolidation time is comparatively less. The mean duration of external fixator was 17.8 weeks (124 days.The results are comparable with the study done by Rozbruch *et al*[14] who noted the mean duration of external fixate was 130 days. In the study done by Tekin[15] and Rozbruch *et al*[16] the mean duration of external fixator was 211.7 days (range, 114–300 days) and 289 days (range, 119-715 days) respectively. In similar study conducted by Ganger *et al*[12], the duration of external fixator was 6.0±1.7 months (range, 2.1-10.6). Patients having long distracting time have long external fixator wearing time.There was residual deformity in 5 (38.5%) patients. Ganger *et al*[12] observed residual deformity in 9.3% patients. Most of the patients in our study were from rural background and failed to comply with the accurate adjustment of struts. The average residual deformity in our study is 7. Similar results are present in the study conducted by Manner *et al*[17], the average residual deformity was 6.8º in patients treated with TSF. We conclude that Distinct advantages of the TSF result from the reduced necessity to build a patient customized frame construct, from its potential for simultaneous multidimensional deformity correction and from the support of precisely working Internet based software. The computer software allows accurate deformity analysis and elaboration of a precise correction protocol. In combination with computer software, by adjusting only the strut lengths on a simple frame, it allows multiplanar corrections also of residual deformities without complex modifications of the device. Thus, the less complicated correction of multidirectional deformities and the easily performed correction of any residual deformities may lead to an enhanced motivation of the treating medical staff, which then again may lead to favorable results for the TSF. Total rate of complications was considerably lower with the TSF.TSF software provides prescription for distraction of struts which make it patient friendly for use. There are limitations for TSF usage too such as, it is not readily available in India, its cost is remarkably higher which limits its frequency to use, there is a steep learning curve, particularly towards usage of TSF software.

REFERENCES

1. Ilizarov GA. The transosseous osteosynthesis: theoretical and clinical aspects of the regeneration and growth of tissue. Berlin: Springer-Verlag; 1992.
2. Köseoğlu E, Yıldız C, Ateşalp AS, Başbozkurt M, Gür E. Treatment of posttraumatic lower limb deformities with the Ilizarov method. [Article in Turkish] Acta Orthop Traumatol Turc 2000;34:480-7.
3. Tolo VT (1983) External skeletal fixation in children's fractures. J Pediatr Orthop 3(4):435–442.
4. Buckley SL, Smith GR, Sponseller PD, Thompson JD, Robertson WW Jr, Griffin PP (1996) Severe (type III) open fractures of the tibia in children. J Pediatr Orthop 16(5):627–634.
5. Blondel B, Launay F, Glard Y, Jacopin S, Jouve JL, Bollini G (2010) Hexapodal external fixation in the management of children tibial fractures. J Pediatr Orthop B 19(6):487–491.
6. Al-Sayyad MJ (2008) Taylor spatial frame in the treatment of open tibial shaft fractures. Indian J Orthop 42(4):431–438.
7. Al-Sayyad MJ (2006) Taylor spatial frame in the treatment of pediatric and adolescent tibial shaft fractures. J Pediatr Orthop 26(2):164–170.
8. Eidelman M, Katzman A (2008) Treatment of complex tibial fractures in children with the Taylor spatial frame. Orthopedics 31(10):992.
9. El Hayek T, Daher AA, Meouchy W, Ley P, Chammas N, Griffet J (2004) External fixators in the treatment of fractures in children. J Pediatr Orthop B 13(2):103–109.
10. Gordon JE, Schoenecker PL, Oda JE, Ortman MR, Szymanski DA, Dobbs MB, Luhmann SJ (2003),A comparison of monolateral and circular external fixation of unstable diaphyseal tibial fractures in children. J Pediatr Orthop B 12(5):338–345.
11. Myers SH, Spiegel D, Flynn JM (2007) External fixation of high energy tibia fractures. J Pediatr Orthop 27(5):537–539.
12. Ganger R, Radler C, Speigner B, Grill F. Correction of post-traumatic lower limb deformities using the Taylor spatial frame. International orthopaedics. 2010 Jun 1;34(5):723-30.
13. D. Dammerer, K. Kirschbichler, L. Donnan, G. Kaufmann, M. Krismer, R. Biedermann, Clinical value

of the Taylor Spatial Frame: a comparison with the Ilizarov and Orthofix fixators, J Child Orthop (2011) 5:343–349.

14. S. Robert Rozbruch MD, Kira Segal BA, Svetlana Ilizarov MD, Austin T. Fragomen MD, Gabriel Ilizarov MD, Does the Taylor Spatial Frame Accurately Correct Tibial Deformities?, Clin Orthop Relat Res (2010) 468:1352–1361.
15. Tekin AC, Çabuk H, Dedeog˘lu SS. The results of bone deformity correction using a spider frame with web-based software for lower extremity long bone deformities SICOT J 2016, pp.2, 11.
16. Rozbruch SR, Pugsley JS, Fragomen AT, Ilizarov S. Repair of tibial nonunions and bone defects with the Taylor Spatial Frame. J Orthop Trauma 2008;22:88-95.
17. Manner HM, Huebl M, Radler C, Ganger R. Accuracy of complex lower-limb deformity correction with external fixation: a comparison of the Taylor Spatial Frame with the Ilizarov Ring fixator, J Child Orthop (2007) 1:55–61 DOI 10.1007/s11832-006-0005-1.

Source of Support: None Declared
Conflict of Interest: None Declared