Original Research Article

Comparison of cellular changes in pituitary gland between the different age groups: A histology-based study

Geetha Jayachandran

Assistant Professor, Department of Anatomy, Government Medical College, Manjeri, Malappuram (Dist), Kerala, INDIA.
Email: sarathgrey@gmail.com

Abstract

Background: Cells in different parts of pituitary gland (PTG) undergo significant changes according to the age. This study was conducted to evaluate the cellular changes in PTG in relation to age with the use of histology observations. **Materials and Methods:** The present study was conducted in Department of Anatomy, A total of 73 PTG specimens were collected from foetus and cadavers. Selected specimens were divided into six groups based on the age [(G-I (Less than 1 Y), G-II (1-10 Y), G-III (11-30 Y), G-IV (31-50 Y), G-V (51-70 Y) and G-VI (Above 71 Y)]. All specimens were subjected to Hand E stain. The histology photos were taken under 40X. The slides were observed for cellular changes in PTG. **Results:** Group-I did not show any cord like arrangement in the periphery and follicular arrangement in the interior. In group-II pars anterior showed cord like arrangement in periphery and follicular arrangement in the interior. Significant changes was observed in the group-III, IV, V and VI compared to other groups regarding cord and follicular arrangement in the peripheral and interior of PTG. There are also significant changes in collagen, acidophils, basophils and cubodial cells in the high age group compared to low age groups. **Conclusion:** There will be significant changes in cellular appearance and its content as age progress. These changes are important in develop hyper and hypo conditions of PTG. Knowledge about histological changes in PTG improves the treatment strategy inpatients suffering from PTG disorders

Key Word: Acidophils, basophils, cord appearance, collagen, histology, zonation

***Address for Correspondence:**
Dr. Geetha Jayachandran, Assistant Professor, Department of Anatomy, Government Medical College Manjeri-676121, Malappuram (Dist) Kerala, INDIA.
Email: sarathgrey@gmail.com
Received Date: 15/12/2018 Revised Date: 02/01/2019 Accepted Date: 23/01/2019
DOI: https://doi.org/10.26611/1001913

Access this article online	
Quick Response Code:	Website: www.medpulse.in
	Accessed Date: 27 January 2019

INTRODUCTION

Pituitary gland (PTG) hormones play major role in maintaining physiological functions of human body. It secretes various stimulatory and inhibitory hormones which can stimulate body cells. The released hormones are required for growth, development (physically and mentally), to attain mile stones as age progress and for thyroid hormone synthesis[1,4]. The hormones secreted by PTG can increase cell growth and stimulate various biochemical enzymes in body. PTG contains various cells which have capacity to synthesis hormones[5,6]. The morphology of each cell is different. The molecular factors that determine hormone production are transcription factors that target specific hormone genes. These factors have clarified three main pathways of cell differentiation. They are somatotrophs, lactotrophs and mammosomatotrophs[7]. Cell proliferation and differentiation are in related to the age. The present study aimed to evaluate the histological changes in PTG with age.

MATERIALS AND METHODS

This study was done in Department of Anatomy. The study protocol was approved by Institutional Human Ethics Committee.

How to cite this article: Geetha Jayachandran. Comparison of cellular changes in pituitary gland between the different age groups: A histology-based study. *MedPulse – International Journal of Anatomy*. January 2019; 9(1): 09-12. http://www.medpulse.in/Anatomy

Inclusion criteria

- Post mortem done within 6 hours of death.
- Cases in which cause of death was not head injury.
- Apparently healthy fetuses.

Exclusion Criteria

- Post mortem done after 6 hours of death.
- Cases in which cause of death was not known or was due to severe head injury.
- Fetuses with congenital neurological anomalies.

Study groups: Based on the inclusion and exclusion criteria total of 73 PTG specimens were collected. They were divided into 6 groups based on the age.

Study groups

Group-I (Less than 1 year),
Group-II (1-10 Y)
Group-III (11-30 Y)
Group-IV (31-50 Y)
Group-V (51-70 Y)
Group-VI (above 71 Y)

After removal of brain, the gland was scooped out from sella turcica after breaking posterior clenoid process. All specimens after removal were immediately transferred to the fixative solution (10% formalinand Bouin's fluid). The stored tissues were used for HandD stain by standard procedure.

Staining of PTG tissue slides: The 10% formalin was also tried as fixative. The whole gland was used as one block without sectioning. After the specimen was fixed, it was dehydrated by placing successively in gradually increasing strength of alcohol solution. The dehydrated specimen were cleared in xylene, impregnated with molten paraffin and then embedded in paraffin wax. Sections were taken from the block at a thickness of 5 microns. Only transverse sections of the gland were taken. The sections after incubation were stained with haematoxylin and eosin. Ehrlich's haematoxylin was used since it could be kept for years after ripening and give a brilliant nuclear stain. The slides were studied under microscope[8].

RESULTS

The glandular cells were uniformly arranged and did not show the cord like arrangement in the periphery and follicular arrangement in the interior. Pars anterior were situated on one side of the cleft. The individual gland cells seemed well spaced. Cells had minimal cytoplasm and vesicular nucleus. The differentiation of zone, that is the peripheral basophilic zone and inner acidophilic zone, was not distinct in very young. In full term foetus a thin peripheral basophilic zone and inner acidophilic zone can be appreciated. Cellularity was found to be significantly increased in full term foetus. In pars anterior and pars intermedia 73% of cells were chromophobes with a mild increase in basophils in full term foetus. Cellularity in pars nervosa was more towards pars intermedia but the difference was not marked. Cleft was seen in all foetus specimens with significant decrease in width as age advances. The shape of the cleft was flattened oval. Cells of the pars anterior and pars intermedia were arranged on either sides of cleft in the form of cords which were widely spaced and they form the lining cells. Vascularity could not be counted. Irregular spaces were seen, however proper sinusoid could be seen only in full term foetus. Small streaks of collagen fibers were seen between cells of pars anterior of full term foetus. Full term foetus showed bundles of collagen fibers in the junction of nervosa with pars intermedia. Capillaries were seen, in full term foetus lying between bundles of collagen. Cells in pars intermedia were arranged in the form of cords with spaces in between. Since cells had less cytoplasm, they seem to be crowded. No cyst and colloid filled follicles were seen in any of the foetus specimens (Figure 1-6).

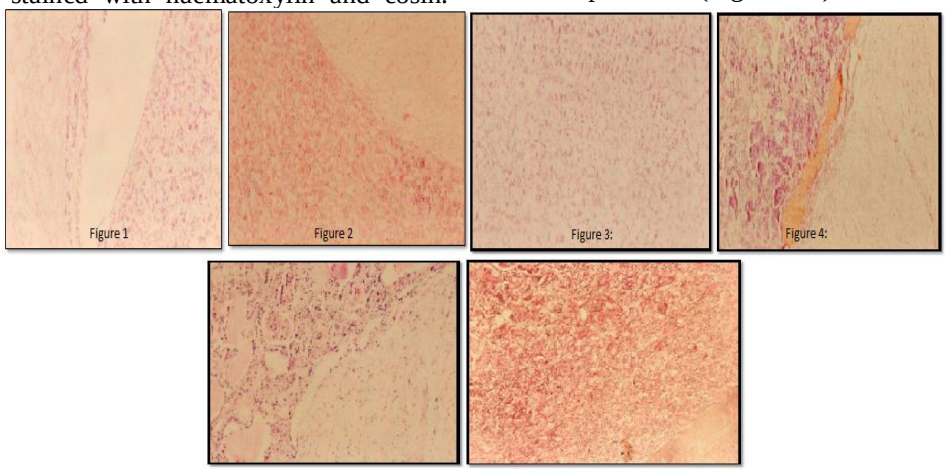

Figure 1: Histology of Group-I pituitary gland, **Figure 2:** Histology of Group-II pituitary gland, **Figure 3:** Histology of Group-III pituitary gland
Figure 4: Histology of Group-IV pituitary gland, **Figure 5:** Histology of Group-V pituitary gland, **Figure 6:** Histology of Group-VI pituitary gland

DISCUSSION

General orientation was more or less similar in all sections of gland. Pars intermedia had maximum thickness in foetal period and proportionate decrease thereafter, followed by maximum decrease in late senility. Typical cord like arrangement in the periphery and follicular arrangement in the interior, as well as the peripheral basophilic zone and inner acidophilic zone were not seen in foetal pituitary except the full term but well seen in all other specimens. As age advanced thickness of peripheral basophilc zone increased and was contributed by chromophobes and basophils, the acidophilic zone also showed an increase in the number of basophils. In foetal specimens, cellularity was found to be significantly increased in all areas. Cells in pars intermedia were arranged in the form of cords with spaces in between. Since cells had less cytoplasm, they appeared to be crowded. There was not much difference in periphery and interior of pars nervosa. In other specimens cellularity was more in the interior than the periphery. A marked increase in cellularity was noted in the interior of pars nervosa from group III onwards. Invasion of pars nervosa by basophils increased as age advanced. Basophilic infiltration was noted from 18-year-old male. Maximum number of invading cells was noted in the oldest age group studied. Fateme S *et al* studied the cell structure changes in PTG of traumatic brain injury patient. In that study it explained that age of the patient can be predicted with use of PTG histology [9]. In the foetus, the increase in cellularity was due to small size of the cells, poorly developed sinusoids and less connective tissue. In young specimens cellularity decreased with increase in cell size and well developed sinusoids. In senility, there were abundant collagen bundles with less number of cells in between and in the adjacent areas. The peripheral basophilc zone in younger age group was due to chromophobes. In older age group it was due to chromophobes and basophils. The inner acidophilic zone was due to closely arranged chromophobes and acidophils. The periphery of pars anterior and pars nervosa were more vascular than their interior. There was decrease in vascularity in pars anterior with age. Vessels in pars anterior had irregular sinusoidal appearance, whereas, those of pars intermedia and nervosa had capillary appearance. Sinusoid was seen as irregular spaces in young foetus. However proper sinusoids could be seen only in full term foetus. Pars nervosa was relatively less vascular. In full term foetus capillaries were seen in pars intermedia, between collagen fibers. Young AM, in his study on ductless gland, studied the changes in histology of PTG. According to him age progression is one of the key factor to induce changes in PTG[10]. Vascularity in pars anterior decreased with increasing age, but blood vessels with capillary like appearance, rather than sinusoids increased number and were seen among bundles of collagen fiber. The capillaries in pars intermedia had increased in size from the age of 30 years and they were found between collagen fibers. In full term foetus, small streaks of connective tissue were seen between cells of pars anterior, and at the junction of nervosa with pars intermedia. Bundles of collagen fibre were seen with a steady increase in the amount of collagen fibre thereafter. They filled the intermedia and run between the follicles. In pars anterior bundles of collagen fiber were seen from age 60 onwards. In late senility, the collagen fibers in pars intermedia infiltrated into the pars nervosa. Study by Mushfika R *et al* showed similar histological changes in PTG[11]. Acidophils were circular, oval or polygonal with vesicular nucleus and eosinophilic cytoplasm. Occasional binucleated acidophils were seen after the age of 50. Basophils predominate the basophilic zone and were cuboidal or polygonal cells with central or eccentrically placed nucleus and basophilic cytoplasm. The cell boundaries of the chromophobes were not distinct as those of the chromophils. Doniach I noted that in age of 50-60 acidophils and bascophils was more compared to other age groups[12]. The present study explained that, as age increases there is significant changes in PTG.

CONCLUSION

In brief, the observations made on the pituitary specimens at different age groups show that the gland does undergo significant changes in relation with age. Knowledge of this may be useful in future studies in the growing field of experimental gerontology. Identification of stem cells that allow the pituitary gland to grow even after birth opens a new field of research that may be adapted in medical research and genetics, in order to advance the understanding and the ability to diagnose and treat cancers, neurological diseases and other causes of human sufferings.

REFERENCES

1. Johannes DV. Changes in pituitary function with aging and implications for patient care. Nat Rev Endocrinol 2013;9(4):205-5.
2. Hartl F, Fischer C. Morphological changes of the human adenohypophysis and their relations to age, sex and constitution. Z Alternsforsch 1955;8(4):301-8.
3. Inger K. Sella turcica morphology and the pituitary gland-a new contribution to craniofacial diagnosis based on histology and neuroradiology. Eur J Orthod 2015;37(1):28-36.
4. John G, Donald H, David W, Jaime RD. Morphological changes in the pituitary adrenocortical axis in natives of la Paz. IJB 1991;35(1):1-5.
5. Donovan BT. Control of synthesis and release of anterior pituitary hormones *invivo*. SSE 1969;187-200.

6. Kazutoshi Y, Niinuma K, Sakar K. Synthesis and storage of prolactin in the pituitary gland of bullfrog tadpoles during metamorphosis. GCE 1986;62(2):247-53.
7. Sarah L, Olaf A. Development and microscopic anatomy of the pituitary gland. Endotext 2000.
8. Al Brahim NYY, Asa SL. My approach to pathology of the pituitary gland. J Clin Pathol 2006;59(12):1245-53.
9. Fateme S, Kalman K, Brend WS. Histologic study of the human pituitary gland in acute traumatic brain injury. Brain Injury 2007;21(6):651-6.
10. Young AM. Pathological changes resulting from excess and deficient secretion of ductless glands. AJCP 1935;5(3):180-210.
11. Mushfika R, Shamim A, Halima A, Nurun N, Anjuman AS. Morphometric study of the human pituitary gland. BJA 2011;9(2):79-83.
12. Doniach I. Histology of the anterior pituitary. CEM 1977;6(1):21-52.

Source of Support: None Declared
Conflict of Interest: None Declared