

# Histomorphological study of malignant tumours with nerve sheath differentiation

Thahseena Abdulla<sup>1\*</sup>, Prema Saldanha<sup>2</sup>

Department of Pathology, Yenepoya Medical College, Mangalore, Karnataka, INDIA.

Email: [thahseenaaz@gmail.com](mailto:thahseenaaz@gmail.com)

## Abstract

**Background:** The malignant peripheral nerve sheath tumour (MPNST) is a rare and aggressive sarcoma that arises from the peripheral nerve sheath, and displays differentiation along the nerve sheath components. Since it exhibits varying growth patterns, and is associated with poor prognosis, it poses a diagnostic challenge. **Methods:** A retrospective descriptive study of cases from the archives of our Pathology Department. The clinical details were obtained from the hospital records. A detailed histopathological study was done and histochemical stains and immunohistochemistry were done wherever required. Tumours were graded using the FNCLCC system. **Results:** Thirteen cases of malignant peripheral nerve sheath tumours were found. The age of the patients ranged from 14 to 75 years (mean 44.5) with a male:female ratio of 1.2:1. There were five cases in the thigh and buttock region, three cases from the spinal region, two cases from intraabdominal region, one case from the distal end of lower limb, and one case each from the forearm and spine. The tumour size ranged from 1.5 cms to 18 cms. Microscopically, the tumours showed varied growth patterns and features of malignancy. All the tumours were S-100 positive. **Conclusion:** The diagnosis of MPNST has been one of the most difficult among the soft tissue tumours because of the lack of standardized diagnostic criteria. The poor prognosis coupled with its varied presentation necessitates an early diagnosis. Immunohistochemistry may be required for confirmation of the diagnosis.


**Keywords:** Malignant peripheral nerve sheath tumour, S-100.

## \*Address for Correspondence:

Dr. Thahseena Abdulla, Department of Pathology, Yenepoya Medical College, Mangalore, Karnataka, 575018 INDIA.

Email: [thahseenaaz@gmail.com](mailto:thahseenaaz@gmail.com)

Received Date: 17/06/2016 Revised Date: 12/07/2016 Accepted Date: 08/08/2016

Access this article online	
Quick Response Code:	Website: <a href="http://www.medpulse.in">www.medpulse.in</a>
	DOI: 15 September 2016

## INTRODUCTION

The tumours from the peripheral nerves include all ranging from benign schwannomas to high grade neoplasms namely malignant peripheral nerve sheath tumours (MPNST). MPNSTs are tumours that arise from peripheral nerves or from extraneural soft tissue showing nerve sheath differentiation. Due to lack of specific morphological criteria owing to low incidence of cases, overlapping morphological features, and rapid disease progression, there is a high probability of misdiagnosing

MPNSTs from non nerve sheath sarcomas and other entities.<sup>1</sup> Nerve sheath tumours arise from tissues considered to be of neuroectodermal or neural crest origin and display a range of features that mirror the various elements of the nerve (e.g., Schwann cell, perineurial cell) and, in rare instances, even appear epithelioid (e.g., epithelioid schwannoma). Benign nerve sheath tumours arising in a nerve are completely surrounded by epineurium or perineurium and, therefore, have a true capsule, a feature that facilitates their enucleation.<sup>2</sup> Any sarcoma with intrinsic involvement of a major nerve without evidence of alternate line of differentiation, or a pre-existing benign nerve sheath tumour, qualifies as an MPNST. Malignant spindled tumours in neurofibromatosis 1 (Nf1) should be considered MPNST unless otherwise proven. In the absence of a major nerve involvement, morphological findings, immunohistochemistry (S-100), ultrastructural finding of Schwann cell, or perineural differentiation, must be present in order to establish the diagnosis.<sup>1</sup> The current study is aimed to study the clinicopathological correlation and histopathological

features of MPNST, and to differentiate from other spindle cell tumours using the criteria by Enzinger.<sup>2</sup> According to Enzinger, a sarcoma is assumed to be an MPNST if one of three criteria can be met: (A) the tumour arises from a peripheral nerve; (B) it arises from a pre-existing benign nerve sheath tumour, usually a neurofibroma; (C) the tumour displays a constellation of histologic features that are seen in tumours arising in the foregoing situations and are generally accepted as reflecting Schwann cell differentiation by light microscopy. These features include the (1) dense and hypodense fascicles alternating in a “marble-like” pattern consisting of (2) asymmetrically tapered spindled cells with irregular buckled nuclei or (3) immunohistochemical or electron microscopic evidence of Schwann cell differentiation in the context of a fibrosarcomatous-appearing tumour. In addition, there are features that are less specific but frequently occur in Schwann cell tumours, including nuclear palisading, whorled structures that vaguely suggest large tactoid structures, peculiar “hyperplastic” perivascular change, and occasionally heterologous elements (e.g., cartilage, bone, skeletal muscle).<sup>2</sup>

**MATERIAL AND METHODS**

**RESULTS**

The archives at our Department of Pathology were searched and patients diagnosed as MPNST from 2008 to 2015 were selected. Cases diagnosed with benign entities of nerve sheath tumours were excluded. The clinical history and radiological findings were collected from the hospital records. The Hematoxylin and Eosin stained slides were examined in detail. Paraffin blocks were retrieved and immunohistochemistry (IHC) was performed to establish the nerve sheath differentiation. The IHC done included S-100 (RTU-S100p: S100 isolated from cow brain: Novocastra, LEICA), Cytokeratin (multicytokeratin-clones AE1andAE3, Novocastra, LEICA), CD 117 (clone T595, Novocastra, LEICA), SMA (RTU-SMA: clone asm-1, Novocastra, LEICA), Desmin (clone DE-R-11, Novocastra, LEICA) and Vimentin (clone V9-Novocastra, LEICA). Immunohistochemical staining was done using Novolink Min Polymer Detection System. Diagnostic criteria were established based on the criteria described by Enzinger, as mentioned earlier<sup>2</sup>. Grading of MPNST tumours was done and the tumours were classified as low and high grade based on the FNCLCC system. (Fédération Nationale de Centres de Lutte Contre le Cancer).

**Table 1:** Details of the cases of the MPNSTs in our study

Details of the cases							
Sr. No	Age	Sex	Site	Size	Nf 1	FNCLCC	
1	38	female	Right thigh	12x6.5x6cm	-	Grade 1	
2	17	female	Proximal forearm	5x4x4cm	+	Grade 1	
3	58	male	Right frontotemporal sac	0.1x0.1cm	-	Grade 3	
4	35	male	Posterior compartment thigh	12x12x0.5cm	-	Grade2	
5	64	male	Pelvis	Largest measuring 15x4x8cm	-	Grade2	
6	38	male	Scalp	13x12cm	-	Grade1	
7	75	female	Left buttock	18x19x8cm	-	Grade 1	
8	19	female	Posterior thigh	21x4x9cm	+	Grade1	
9	60	male	Right kidney	16x12x9cm	-	Grade 2	
10	14	female	Scalp	Largest measuring 11.2x5x3cm	+	Grade3	
11	20	male	Posterior thigh	10x7x6cm	+	Grade3	
12	30	female	Spine (L3-5)	Linear bits measuring 1.5cm in greatest dimension	-	Grade 1	
13	63	male	Left leg	18x12x8cm	-	Grade 3	

Thirteen cases of malignant peripheral nerve sheath tumours were diagnosed. The details are given in Table 1. The age of the patients ranged from the age of the patients ranged from 14 to 75 years (mean 44.5). There was a slight male preponderance, with a male:female ratio of 1.2:1. Four out of 13 (31%) cases showed Nf1 association. These patients presented below the age of 20. They exhibited some of the clinical features that suggested Nf1 association, like the presence of six or more café au lait spots, freckles in axilla or groin,

multiple neurofibromas and Lisch nodules. Most of the lesions were deep seated constituting upto 80% of the lesions and only 20% presented as superficial masses. Five cases presented from the thigh and buttock region, three cases from the spinal region, two cases from intra abdominal region and one case each from the forearm, spine and lower leg (Figures 1 and 2). The tumour was seen in sizes ranging from 1.5cms to 18 cms. Most of the cases presented with tumour sizes >5cm in diameter except for 2 cases.



Figure 1

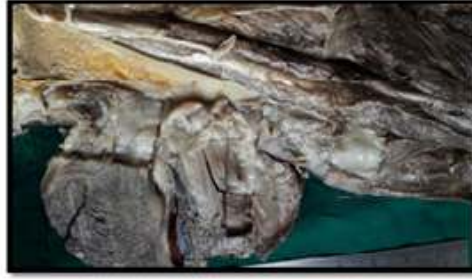

Figure 2

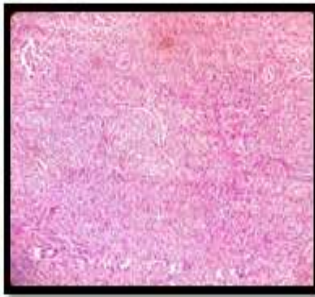


Figure 3

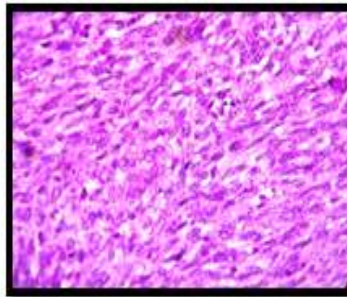


Figure 4

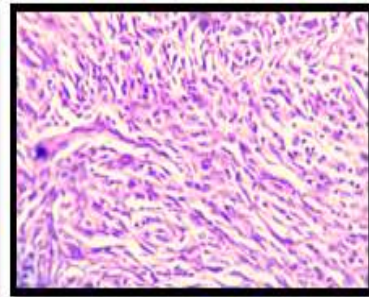


Figure 5

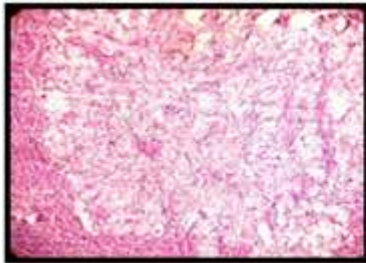


Figure 6

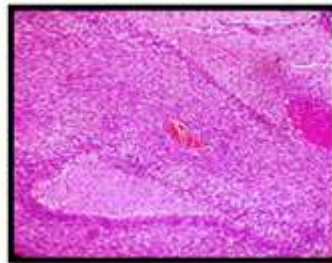


Figure 7

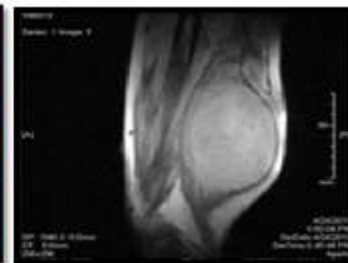

Figure 8

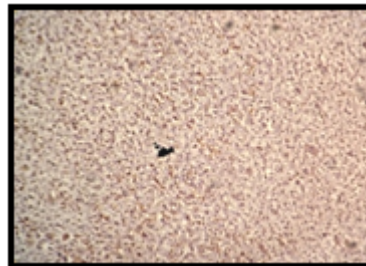


Figure 9

**Legend**

**Figure 1:** A case of a 60 yr old gentleman showing a superficial globular mass on the left leg measuring 18 x12 x 8 cm; **Figure 2:** Cut section of the mass in figure 1 reveals solid, homogenous and fleshy cut surface; **Figure 3:** (HandE X4) Low power view shows tumour cells arranged in sweeping fascicles and sheets; **Figure 4:** (HandE X40) showing epithelioid cells with vesicular to hyperchromatic nuclei, showing punched out appearance. Few nuclei also show prominent nucleoli; **Figure 5:** (HandE X40) The buckling of nuclei with indistinct cytoplasm and cell margins is seen here; **Figure 6:** (HandE X4) Low power view in 5X, showing myxoid change in the stroma; **Figure 7:** (HandE X4) Area showing geographic necrosis with the surrounding cells showing palisading; **Figure 8:** MRI right thigh image showing a heterogeneously enhancing large spindle shaped altered signal intensity lesion in the posterior aspect of femur in the intermuscular plane measuring 112x80x66mm, causing stretching and displacement of the muscles in the posterior compartment of thigh suggestive of mesenchymal tumour (NEUROGENIC); **Figure 9:** (HandE X4) Strong positivity for S-100 antigen.

Histological analysis included observation of varying patterns, with pleomorphic spindle to oval shaped spindle cells arranged in either storiform pattern, herring bone pattern and sweeping fascicles (Figure 3). Hemangiopericytoma like vascular pattern was also seen

in few cases. The individual cells invariably showed dark, punched out appearing nucleus, and indistinct cytoplasmic borders (Figure 4). Most of the cases showed buckling of nuclei and few cases showed nuclei with vesicular chromatin with prominent nucleoli (Figure 5).



The presence of bizarre cells, tumour giant cells and mitotic figures, both typical and atypical were noted. The stroma showed myxoid areas and lymphocytic infiltration in all the cases, and some cases showed collagen bundles, prominent blood vessels and hyalinised areas (Figure 6). The borders showed infiltration into the surrounding structures, and 50% of the cases also saw the presence of nerve bundles. Areas of geographic necrosis were seen in few of the cases with peripheral palisading of nuclei (Figure 7). One of the cases was diagnosed as epithelioid variant of malignant peripheral nerve sheath tumour. Tumour necrosis, which is an important feature in the FNCLCC, and an important indicator in the WHO grading system, was observed in seven of the resected specimens, upgrading the grade of the tumours in biopsies by the time of resection. Clinical and radiological assessment of the cases suggested MPNST as one of the differential diagnosis among other soft tissue tumours (Figure 8). Only three cases in our study could be diagnosed as MPNST radiologically. Association with neurofibromatosis was an important parameter in pointing at the diagnosis clinically. The differential diagnoses that we had to tackle were fibrosarcoma, dermatofibrosarcoma, metastasis, meningioma, giant cell chordoma, and malignant round cell tumour. The differential diagnoses were ruled out using appropriate immunohistochemical markers. S-100 positivity was observed in all cases, and one case showed very strong positivity (Figures 9).

## DISCUSSION

MPNST is an aggressive and rare sarcoma. It was previously categorized under different names which included neurogenic sarcoma, malignant schwannoma and neurofibrosarcoma.<sup>3</sup> In the present study, a total of 13 cases of MPNSTs were studied. A wide age range was seen from 14 to 75 years. Majority of cases were seen in the 2nd to 4th decade. This corresponds to the age range in the study of Rekhi *et al*<sup>4</sup> where the patients' age ranged from 8 to 75 years. In their study, the mean age at presentation was 38.1 years. In the present study we had a slight male preponderance with male: female ratio being 1.2:1 which is at par with most studies.<sup>4,5,7</sup> Kar *et al.* also found that extremities were the common site involved followed by chest wall, trunk, pelvis, head and neck, and they opined that MPNSTs occurred frequently in males with median age of 40 years.<sup>(5)</sup> But in contrast to all that, Ducatman *et al.* found that trunk was the most common site (46%) involved by MPNSTs in their study.<sup>6</sup> The association of MPNSTs with Nf1 is well known, and Hirose *et al* reported that 5%-42% Nf1 patients developed MPNST<sup>3</sup> which is in accordance with our study where 33% (4/12 cases) showed an association with

neurofibromatosis. Ducatman *et al.* in their study opined that MPNST in Nf1 patients is more common than in the general population.<sup>6</sup> However, according to Shashidharan *et al*, only 18% of the cases showed Nf1 association.<sup>(7)</sup> Patients with Nf1, develop MPNST at a younger age, as shown in studies by Ducatman *et al*, where the mean age of presentation was 28.7 years than patients without Nf1 (mean age - 39.7 years) in the studies by Ducatman *et al.*<sup>6</sup> In the study by Shashidharan *et al*, they found one patient with Nf1 presented at 50 years and other patient at 18 years.<sup>7</sup> Sometimes chondroid differentiation may be encountered in MPNSTs. The presence of heterologous elements was not found to have a significant impact on survival, in the studies by Ducatman *et al.* and Kar *et al.*<sup>5,6</sup> None was observed in our cases. The tumours were diagnosed either as MPNSTs or other neural tumours based on the microscopic features described above. IHC with S-100 protein was done in all the cases; a positive expression of S-100 protein in all the cases and negative expression of several other markers helped us to confirm the diagnosis. Ducatman *et al*<sup>6</sup> also observed that tumours in the extremities had a better outcome than cases in the head and neck but Kar *et al*<sup>5</sup> opined that site of the tumour had no impact on the survival of the patients. Rekhi *et al*<sup>4</sup> opined that this might be due to the possibility of better clearance in extremity lesions. Enzinger opined that grade of the tumour, necrosis, vascular invasion and presence of mitoses have a significant influence on survival of the patients.<sup>2</sup> The French system for grading tumours relies on the evaluation of tumour differentiation score, mitoses and necrosis; however, its main weakness lies in the assignment of the differentiation score. Differentiation score is defined as the extent to which a tumor resembles adult mesenchymal tissue (score 1), the extent to which the histologic type is known (score 2), or the observation that the tumor is undifferentiated (score 3).<sup>2</sup> Keeping all this in mind, diagnosing and grading a poorly differentiated MPNST is indeed a diagnostic challenge.

## CONCLUSION

This series highlights clinicopathological features of 13 cases of MPNSTs and its association with Nf1. S-100 staining was performed in all of them and was found to be positive in all the cases. Positive expression of S-100 protein in all the cases and negative expression of other markers helped us to rule out the differential diagnoses. Positivity of S-100 protein was found to be the most reproducible marker in this tumour. Thus, a combination of clinical history, gross, microscopic examination and immunohistochemistry aided in diagnosing these tumours.

## REFERENCES

1. Rodriguez FJ, Folpe AL, Giannini C, Perry A. Pathology of Peripheral Nerve Sheath Tumors: Diagnostic Overview and Update on Selected Diagnostic Problems. *Acta Neuropathol.* 2012 March; 123: 295–319.
2. Weiss SW, Goldblum JR. *Enzinger and Weiss's Soft Tissue Tumours*, 5<sup>th</sup> ed: Mosby Elsevier, China, 2008; 903-25.
3. Hirose T, Scheithauer BW, Sano T. Am J surgical Patho Perineural malignant peripheral nerve sheath tumor (MPNST): a clinicopathologic, immunohistochemical, and ultrastructural study of seven cases. 1998 Nov; 22:1368-78.
4. Rekhi B, Ingle A, Kumar R, De Souza MA, Dikshit R, Jambhekar NA. Malignant peripheral nerve sheath tumours: Clinicopathological profile of 63 cases diagnosed at a tertiary cancer referral centre in Mumbai, India. *Indian J Pathol Microbiol* 2010; 53:611-8.
5. Kar M, Deo AV, Shukla NK, Malik A, Gupta SD, Mohanti BK, et al. Malignant peripheral nerve sheath tumors (MPNST) - clinicopathological study and treatment outcome of twenty-four cases. *World J Surg Oncol.* 2006; 4:55.
6. Ducatman BS, Scheithauer BW, Piepgras DG, Reiman HM, Ilstrup DM. Malignant peripheral nerve sheath tumors. A clinicopathologic study of 120 cases. *Cancer.* 1986 May 15; 57:2006-21.
7. Sasidharan SV, Kumar V, Pai R V, Vasudevan S. *International Journal of Research in Medical Sciences.* Int J Res Med Sci. 2014 Nov; 21307-12.
8. Yamaguchi U, Hasegawa T, Hirose T, Chuman H et al. Low grade malignant peripheral nerve sheath tumour: varied cytological and histological patterns. *J Clin Pathol* 2003; 56:826–30.
9. Rosai J. *Rosai and Ackerman's Surgical Pathology*, 10<sup>th</sup> ed Elseviers, Missouri, 2011; 2137-40.
10. Kumar VK, Abbas A, Robbins and Cotran *Pathologic Basis of Disease*. 9th ed. Elseviers, Canada, 2015. 1248-9.

Source of Support: None Declared  
Conflict of Interest: None Declared