

# Occurrence and anatomical distribution of myocardial bridges and co-relation with sudden death and coronary atherosclerosis

Rajendra Prasad. V. K. \*, Joseph T. John \*\*, Supriya N. K. \*\*\*

\*Assistant Professor, Department of Forensic Medicine, Government Medical College, Thrissur, Kerala, INDIA.

\*\*Professor and HOD, Department of Forensic Medicine, Amala Institute of Medical Sciences, Thrissur, Kerala, INDIA.

\*\*\*Professor, Department of Pathology, Government Medical College, Kozhikode, Kerala, INDIA.

Email: [drjosephjohn@hotmail.com](mailto:drjosephjohn@hotmail.com)

## Abstract

Human hearts from four hundred consecutive medico legal autopsies were examined morphologically and histopathologically, for myocardial bridges, in Departments of Forensic Medicine and Pathology, at Medical College, Calicut, Kerala state, South India. Only twenty two among the four hundred cases showed myocardial bridging, indicating low incidence in Keralites compared to Northwest Indians, Taiwanese, Japanese, Czechs and Brazilians. Eighteen cases occurred in age group between twenty and sixty, and nineteen in males. Both observations were, but, statically insignificant. Cause of death in sixteen cases was established to be non cardiac, in two cases, suggestive of poisoning, and in the remaining four cases, clearly suggestive of Coronary Artery Disease due to atherosclerotic narrowing. Hence, the role of myocardial bridges in causing death, at the most, could be only contributory in the latter four cases. Right coronary artery (RCA) presented myocardial bridging in one case, contradicting the observation, in several studies, of myocardial bridges occurring only in left anterior descending coronary artery (LAD). Atherosclerosis was histopathologically confirmed in the tunneled segments in twenty one out of the twenty two cases, which negated the common finding that the tunneled arteries were free from occurrence of Atherosclerosis.

**Keywords:** Myocardial Bridge, Tunneled artery, Atherosclerosis.

## \*Address for Correspondence:

Dr. Joseph T. John, Professor and HOD, Department of Forensic Medicine, Amala Institute of Medical Sciences, Thrissur, Kerala, INDIA.

Email: [drjosephjohn@hotmail.com](mailto:drjosephjohn@hotmail.com)

Received Date: 04/03/2015 Revised Date: 11/11/2015 Accepted Date: 08/10/2016

Access this article online	
Quick Response Code:	Website: <a href="http://www.medpulse.in">www.medpulse.in</a>
	DOI:

## INTRODUCTION

Reyman in 1737 noted that some individuals had cardiac muscle fibres overlying the intra myocardial segments of epicardial coronary arteries. Such overlying myocardial fibres were called as “Myocardial Bridges” and the segments of arteries underneath them as “Tunneled Arteries”<sup>1</sup>. Myocardial bridging, a congenital anomaly, usually located over the mid portion of left anterior

descending coronary artery (LAD) and exceptionally over the diagonal, obtuse marginal or posterior descending branches<sup>2,3</sup>, can cause systolic compression of tunneled segments. Clinically most patients with myocardial bridges are asymptomatic, but angina, acute myocardial infarction, ventricular fibrillation, myocardial ischemia, cardiac arrhythmias and sudden death are reported in some<sup>4</sup>. Isolated myocardial bridges of LAD have been reported in postmortem studies of young individuals, who died suddenly during strenuous exercises<sup>5</sup>. Contraction of the perivascular myocardium, particularly at accelerated heart rates may cause occlusion of blood flow within tunneled arteries<sup>6</sup>. In depth analysis of autopsy samples was first presented by Geiringer *et al*<sup>7</sup>. Estimation of prevalence of myocardial bridges in the local population was thus necessitated and was undertaken in this study by assessing their presence in medico legal autopsies, so that their distribution and relationship with sudden death and coronary atherosclerosis can be estimated.

## MATERIALS AND METHODS

This study was conducted in four hundred consecutive medico legal autopsies conducted between January 2006 and April 2006, examined morphologically and histopathologically, for myocardial bridges, in Departments of Forensic Medicine and Pathology, at Medical College, Calicut, Kerala State, South India. All intact hearts, irrespective of age, sex and cause of death were included, but nineteen, out of four hundred and nineteen autopsies conducted during this period, were excluded due to advanced decomposition, skeletonization or mechanical trauma to heart. Personal history from live-in-relations and details of death from police were collected in all cases, along with perusal of clinical records. Serial sections of all coronary arteries were made at 2mm intervals, using size 12 Bard Parker blades. As no case showed calcification of tunneled or non tunneled segments, decalcification was not attempted. Dissected specimens, preserved in ten percent formalin, were subjected to histo pathological examination, by paraffin sectioning and haematoxylin and eosin staining.

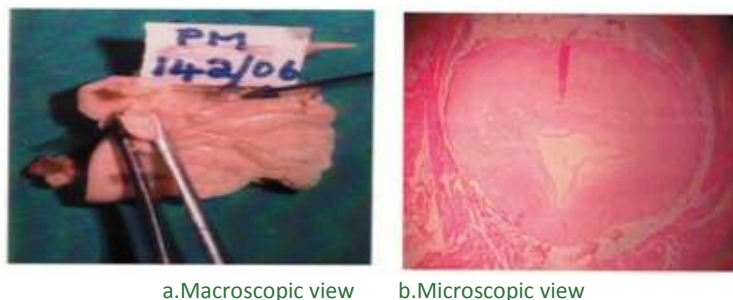


Figure 1: Tunneled Right Coronary Artery(Showing atheromatous plaque)

Sixteen of the cases with myocardial bridging had established cause of death, not at all related to tunneling, like hanging, physical injuries, poisoning, strangulation or electric contact. Two cases suggested death due to poisoning and remaining four died of established coronary artery disease. Status of coronary artery in the latter four cases is shown in table 1.

Table 1: Minimum lumen Size in relation to Atherosclerosis in percentage

No.	Site of Myocardial Bridging	Minimum lumen Size in relation to Atherosclerosis in percentage			
		LM	LAD	LC	RCA
01	Middle third of LAD	66	01	66	66
02	-do-	100	25	01	40
03	-do-	10	20	01	01
04	-do-	33	33	66	100

LM = Left main coronary artery; LAD = Left anterior descending coronary artery; LC = Left circumflex coronary artery; RCA = Right coronary artery

## RESULTS

Twenty two out of four hundred cases showed myocardial bridging (5.5%). Eighteen cases were below the age sixty years (81.8%). While nineteen out of three hundred cases of males (6.33%) showed myocardial bridging, only three out of hundred females had such bridging (3 %). No case of myocardial bridges was seen in the age group under twenty years and in those over eighty years. Eighteen cases were between twenty and sixty years (81.82%) and remaining four between sixty and eighty years (18.18%). Eighteen of the cases with myocardial bridging had no associated history of cardiac symptoms. However, one of the remaining four cases had history of occasional attacks of syncope, another had history of heart disease and chest pain, and yet another chest pain alone. No history could be elicited from one. All showed Myocardial bridging at middle 3<sup>rd</sup> of LAD, but one had it at middle 3<sup>rd</sup> of RCA also. (Fig 1). Nine cases (5%) revealed atherosclerosis in tunneled segments by gross examination. Histo pathological examination revealed atherosclerosis of tunneled segments in all the cases, except one (95.45%).

## DISCUSSION

The finding of myocardial bridging ,5.5% only, compared to the percentage of occurrence found in other studies such as Geiringer (22%), Polacek (85.7%) and Ferreria (55.6%), revealed low incidence of myocardial bridging in North Keralites, compared to Northwest Indians, Taiwanese, Japanese, Czechs and Brazilians. No case of myocardial bridges was seen in age group less than twenty years and over eighty years. Eighteen cases were between twenty and sixty years (81.82%) and remaining four between sixty and eighty years (18.18%). Prevalence was found to be higher in males (6.33%) than females (3%). Myocardial bridging causing death, as a single entity could be excluded, since, in all cases death was due to other established causes like hanging, physical injuries, poisoning, strangulation, electric contact or coronary artery disease. Higher percentage of occurrence in higher age group (81.8%) indicated longer survival, in spite of myocardial bridging. Findings confirmed that myocardial bridging can occur in coronary arteries other than LAD

also, but less frequently. Such tunneled arteries can suffer from atherosclerosis, in contrast to the conclusions of Geiringer, that such segments are spared from atherosclerosis.

## CONCLUSION

1. Low incidence of myocardial bridging prevails in north Keralites of South India.
2. Myocardial bridging, if occurs, affects LAD more frequently than other coronary arteries.
3. Tunneled arteries also suffer from atherosclerosis.
4. Myocardial bridging causing death as a single entity could be excluded.

## REFERENCES

1. Reyman HC: Disertatio de vasis cordis propiis, Med Diss Univ Gottingen, 7<sup>th</sup> September 1737; 1-32 in Stefan Mohlenkamp, Waldemar Hort, Junbo Ge, Fainmund Erbel, Update on Myocardial Bridging, Circulation, 2002;106:2616-2622.
2. Geiringer E: The Mural Coronary, Am Heart J. 1951;41:359-368 in Ji-Shen Chen, Chin-Lon Lin, Myocardial Bridging, Tzu Chi Med J 2003-15-No.6.

3. Polacek P: Relation of Myocardial Bridges and Loops on the Coronary Arteries to Coronary occlusion, Am Heart J 1961; 61:44-52,in Ji-Shen Chen, Chin-Lon Lin, Myocardial Bridging, Tzu Chi Med J 2003-15-No.6.
4. Smith SC, Taber MT, Robiolio PA, Lasala JM: Acute Myocardial Infarction Caused by a Myocardial Bridge Treated with Intracoronary Stenting, Cathet Cardiovasc Diagn 1997; 42:209-12, in Vanildo Junior de Melo Lima, Jenecy Sales Cavalcanti, Testuo Tashiro, Myocardial Bridges and their Relationship to the Anterior Interventricular Branch of the Left Coronary Artery, Arq Bras Cardiol,2002; Volume 78(No.3):219-22.
5. Bestetti RB, Costa RS, Kazava DK, Oliveira JS: Can Isolated Myocardial Bridging of the Left Anterior Descending Coronary Artery be Associated with Sudden Death during Exercise? Acta Cardiol 1991; 46:27-30,24 in Ji-Shen Chen , Chin-Lon Lin, Myocardial Bridging, Tzu Chi Med J 2003-15-No.6
6. Shotar A, Busuttill A: Myocardial Bars and Bridges and Sudden Death, Forensic Science Int 1994: Oct 21:68(3):143-7
7. Geiringer E: The Mural Coronary, Am Heart J.1951; 41:359-368,in Stefan Mohlenkamp, Waldmer Hort, Junbo Ge, Fainmund Erbel, Update on Myocardial Bridging, Circulation 2002; 106:2616-2622.

Source of Support: None Declared  
Conflict of Interest: None Declared