

Efficacy and safety of conjunctival auto graft and amniotic membrane graft after primary pterygium excision

Dhuwadhapare Pravinkumar Gangadhar^{1*}, Choudhary Kashinath G², Khaire Bhaskar Shankar³

¹Speciality Medical Officer, V N Desai Municipal General Hospital, Santacruz (E), Mumbai-55, Maharashtra, INDIA.

²Assistant Professor, ³Professor and HOD, Department of Ophthalmology Government medical college Aurangabad, Maharashtra, INDIA.

Email: pravindhuwadhapare@gmail.com

Abstract

Introduction: Pterygium is a degenerative condition of sub-conjunctival tissue which proliferates as vascularised granulation tissue to invade cornea, destroying the superficial layers of stroma and Bowman's membrane; the whole being covered by conjunctival epithelium. The mainstay of treatment is surgical. There are numerous surgical procedures that have been advocated for the surgical management of pterygia and each has advantages and disadvantages. **Aims and objectives:** To study the efficacy and safety of Conjunctival auto graft and Amniotic membrane graft after primary pterygium excision. **Material and Method:** fifty cases of primary pterygium were enrolled in the study and were divided in two groups of 25 patients each. After receiving institutional ethical committee approval and informed consent from patients the study was conducted. Group A patients underwent pterygium excision with conjunctival auto-grafting whereas Group B patients underwent pterygium excision with amniotic membrane grafting. All the patients were observed keenly for any intra operative and post operative complication. Postoperative follow up was done to find any recurrence. **Results:** Mean age of patients in group A was 43.16±12.60 years whereas in group B mean age was 42.48±12.20 years. Majority of the patients in both groups were having nasal pterygium (96% each). No patient had intra-operative complications in group A. In group B one patient had intra-operative graft tear. In group A, 5 (20%) patients had subconjunctival hemorrhage, 4 (16%) patients had immediate post operative graft edema, 2 (8%) patients had foreign body granuloma, 1 patient (4%) had graft infection and in group B, 1 (4%) patient had intraoperative graft tear at the time of suturing, 3 (12%) patients had subconjunctival hemorrhage, 2 (8%) patients had foreign body granuloma. None of these had any long term effect on outcome of surgeries. There was recurrence of pterygium in 1 (4%) case each in both groups. **Conclusion:** Both amniotic membrane grafting and conjunctival autografting are equally safe and effective procedures for the management of primary pterygium. And Amniotic membrane grafting is viable alternative to conjunctival autografting.

Keywords: primary pterygium, recurrence, conjunctival autografting, Amniotic membrane grafting.

* Address for Correspondence:

Dr. Dhuwadhapare Pravinkumar Gangadhar, Speciality Medical Officer, V N Desai Municipal General Hospital, Santacruz (E), Mumbai-55, Maharashtra, INDIA.

Email: pravindhuwadhapare@gmail.com

Received Date: 02/01/2015 Revised Date: 12/12/2015 Accepted Date: 12/10/2016

Access this article online	
Quick Response Code:	Website: www.medpulse.in
	DOI:

INTRODUCTION

Pterygium is a degenerative condition of sub-conjunctival tissue which proliferates as vascularised granulation tissue to invade cornea, destroying the superficial layers of stroma and Bowman's membrane; the whole being covered by conjunctival epithelium. The lesion thus appears as a triangular encroachment of conjunctiva upon cornea with numerous small opacities lying deeply in front of its blunt apex. Pterygium when single is usually on nasal side and when double, the temporal lesion appears latter. In early stages it is thick and vascular, become thin and pale when it ceases to grow, but never disappears.¹ The major complaint of the patient is

cosmetic or dimness of vision. Dimness of vision is mostly due to astigmatism but may be due to encroachment over pupillary area of the cornea by the lesion. Some patients may be conscious of some fleshy mass growing onto the cornea.² Exact cause of pterygium is not known. Outdoor work in situations with high light reflectivity, including from sand and water enhances pterygium development and use of hats and sunglasses is protective.³ The mainstay of treatment is surgical. There are numerous surgical procedures that have been advocated for the surgical management of pterygia and each has advantages and disadvantages. The ideal surgical procedure for this condition should be simple to perform, fast, with an acceptable complication rate, have very low recurrence rate and good cosmesis. Unfortunately none of the currently available technique fulfils all these criteria.⁴ The excision of pterygium with no added therapy (“bare sclera excision”) was widely practised; but it was associated with unacceptably high recurrence rate; in India approximately 32%. Several methods were implemented with the aim of improving success rate; among them transplantedation of head of pterygium conjunctival flaps, conjunctival autografts, lamellar keratoplasty, mucous membrane graft, skin graft, chemotherapy by thiotepa or mitomycin-C, radiation therapy by radon bulbs, radium plaques, X-ray or Strontium -90 irradiation. Several of them succeeded in lowering recurrence rate but did so at the price of site threatening complications from the tissue damage associated with the treatment. So safety of techniques should also be taken into consideration.⁵ Thus the present study was conducted to determine safety, efficacy, recurrence rate of two commonly used procedures of pterygium treatment, viz, conjunctival autografting and amniotic membrane grafting.

AIMS AND OBJECTIVES

To study the efficacy and safety of Conjunctival auto graft and Amniotic membrane graft after primary pterygium excision.

MATERIAL AND METHOD

The present prospective study was conducted in ophthalmology department of Govt. Medical College and Hospital, Aurangabad from November 2001 to November 2013. After receiving the approval from Institutional Ethical Committee the study was conducted. For the purpose of study, patients of varying degree of pterygium reporting to our OPD, fitting in the following inclusion and exclusion criteria were selected.

Inclusion Criteria

- Primary pterygium

Exclusion Criteria

- History of trauma to same eye.

- Other Corneal diseases such as Cornea Dystrophies, Cornea Degeneration or Cornea Opacities.
- Previous Pterygium Excision surgery in same eye.
- Any other ocular surgery in same eye.
- Posterior Segment Anomalies.

Thus with references to above mentioned inclusion and exclusion criteria total fifty patients who were willing to give informed consent for surgery were enrolled into the study. After properly selecting the patients they were randomly distributed in two groups, with 25 patients in each group.

Group A: underwent pterygium excision with conjunctival auto-grafting

Group B: underwent pterygium excision with amniotic membrane grafting

A detailed demographic, ocular, medical and surgical history was taken and recorded on a prestructured proforma. An elaborate ocular examination was performed. All patients were operated on OPD basis. Informed and written consent was obtained from patient. All the surgeries were performed by a single experienced surgeon. Procedure was done under peribulbar anaesthesia. Pterygium excision was done and as per group allotted, either conjunctival autografting or amniotic membrane grafting was done for closure of bare area. Systemic antibiotics and analgesics were given for 3 days post operatively. Next day eye pad removed and slit lamp examination was carried out. Post operatively, dark goggle was advised and topical preparations were given, i.e. steroid antibiotic eye drops in tapering doses for 4 weeks or till inflammation subsides and artificial tear drops. Patient was explained post operative care to avoid dust exposure, rubbing of eyes and was explained regular follow up. Review postoperative examination will be carried out on day- 2nd, 7th, 15th, 30th and 6 months after surgery. All the patients were followed up to looked for any post operative complication and recurrence of pterygium.

RESULTS

Table 1: Demographic features of patients and site and grade of pterygium

Variable		Group	
		A (n=25)	B (n=25)
Age in years	Mean ± SD	43.16 ± 12.60	41.80 ± 12.00
	Sex		
	Male	5 (20%)	11 (44%)
	Female	20 (80%)	14 (46%)

Site of pterygium	Nasal	24 (96%)	24 (96%)
	Temporal	1 (4%)	0 (0%)
	Double headed	0 (0%)	1 (4%)
Eye involved	RE	11 (44%)	10 (40%)
	LE	8 (32%)	9 (36%)
	BE	6 (24%)	6 (24%)
Grade of pterygium	I	1 (4%)	1 (4%)
	II	15 (60%)	18 (72%)
	III	9 (36%)	6 (24%)

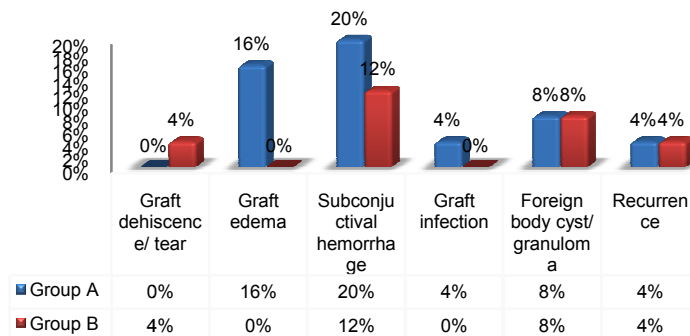
The age of patients in the present study was ranged from 24 to 65 years. Mean age of patients in group A

(underwent pterygium excision with conjunctival auto-grafting) was 43.16 ± 12.60 years whereas in group B (underwent pterygium excision with amniotic membrane grafting) mean age was 42.48 ± 12.20 years. There was no statistically significant difference in age of patients among group A and group B. There were 5 males (20%) and 20 females (80%) in Group A and 11 males (44%) and 14 females (46%) in group B. There was no statistically significant difference in sex distribution among group A and group B. Majority of the patients in both groups were having nasal pterygium (96% each). Unilateral pterygium was common in our study with right side predominance. Majority of the patients were suffering from grade II pterygium (group A: 60% and group B: 72%) followed by grade III (group A: 36% and group B: 24%). There was no statistically significant difference in group A and group B, in view of grade wise distribution pterygium.

Table 2: Distribution of patients according to complications

Complications		Group A (n=25)	Group B (n=25)
Intra-operative complications	Graft dehiscence/ tear	00	01 (4%)
	Graft edema	04 (16%)	00
Post-operative	Subconjunctival hemorrhage	05 (20%)	03 (12%)
	Graft infection	01 (4%)	00
	Foreign body cyst/ granuloma	02 (8%)	02 (8%)
Recurrence		01 (4%)	01 (4%)

Distribution of patients according to complications.



It was observed that no patient had intra-operative complications in group A. In group B, intra-operative graft tear had occurred at time of suturing in 1 case (4%) which was replaced with another graft in same sitting and procedure was ultimately completed uneventfully. No other intra-operative complication was noted. Immediate post operative graft edema was observed in 4 cases (16%) of group A. however no case of graft edema was observed in group B. Subconjunctival hemorrhage was observed in 5 cases (20%) in group A whereas in 3 cases (12%) of group B. Graft infection was observed in one case (4%) of group A, which was successfully managed by appropriate topical and systemic medications. There was no similar complication in group B. Both groups had 2

cases (8%) each of foreign body granuloma, which required surgical removal of suture and granuloma in operation theatre, but the graft was successfully preserved in all four cases and there was no recurrence of the granuloma was found in the subsequent follow ups. Recurrence rate of pterygium by both the methods was 4%. Recurrence of pterygium was observed in one case each in both the groups at around 3 months postoperatively.

DISCUSSION

The present study was conducted on 50 eyes of 50 patients with primary pterygium without any other ocular pathology, to determine the surgical outcomes of two

commonly used procedures of pterygium treatment, viz; conjunctival autografting and amniotic membrane grafting in terms safety, efficacy and recurrence rate. Mean age of the patients in the study was 43.16 ± 12.60 years in group a, 41.80 ± 12.00 years in group B and over all mean age 42.48 ± 12.20 years. Both the groups were comparable as there was no statistically significant difference in age of patients among group A and group B. (By unpaired students t test, $P=0.6979$). Similar findings were also reported by Dr. Rao S. K. *et al*⁶ (42.7 ± 14.5 years) and Shrestha A. *et al*⁷ (43 ± 7.97 years) in their study. According to Cameron⁸ pterygium affects people living in pre-equatorial regions. The disease affects preferentially adults over the middle age being relatively rare in children; the highest incidence is in fourth decades. So, age profile of our study population was matching with similar other studies. In our study, Group A had 5 males (20%) and 20 females (80%) while group B had 11 males (44%) and 14 females (46%). Statistically both groups were comparable in sex distribution (By Fishers exact test, $P=0.1284$). Thus the female predominance was observed in the present study. Similar findings were also reported by David Hui-Kang Ma *et al*.⁹ In contrary to our findings male predominance was reported by Dr. Rao S. K. *et al*⁶, Lu P. *et al*¹⁰ and Shrestha A. *et al*⁷. The possible difference may be due to the fact that quite majority of our patients came for treatment cosmetic disfigurement caused by pterygium. Also, as most of the women in our study came from lower socioeconomic class and rural areas; were exposed more to 'chullah' smoke and outdoor work, it may point towards one of the etiological factors in development of pterygium. Out of 50 cases, 48 (96%) were having nasal pterygium, while 1 case each (2%) was of temporal pterygium and double headed (Nasal + Temporal) pterygium. Luanratnacorn P *et al*¹¹ and Maheshwari S¹² also reported nasal pterygium as common side in their study. Bilateral pterygium was present in 12 (24%) patients, while 38 (76%) were having unilateral pterygium. The nasal affinity of pterygium was attributed to the sparseness of the subconjunctival tissue in the temporal region and the temporal region is exposed to lesser extent to U.V. radiation due to greater amount of bowing of outer 2/3 of the upper lid. Majority of the patients were suffering from grade II pterygium (group A: 60% and group B: 72%) followed by grade III (group A: 36% and group B: 24%). There was no statistically significant difference in group A and group B, in view of grade wise distribution pterygium. Maheshwari S¹² also observed grade II and grade III as the common type in their study. In group A cases, no patient had intra-operative complications. While in group B, in 1 case (4%) intra-operative graft tear had occurred at time of suturing,

which was replaced with another graft in same sitting and procedure was ultimately completed uneventfully. No other intra-operative complication was noted. Intra-operative graft tear that occurred in a patient of group B could be due to delicate nature of thin amniotic membrane. It occurred in one of first group of patients posted for amniotic membrane grafting and didn't got repeated latter on in any patient in study. So, it can also be due to technical error at surgeon's part. It should also be noted here that, as tear occurred in amniotic membrane grafting we could replace it with another graft of amniotic membrane. But if such large tear would have occurred with patient with conjunctival auto graft, one would have needed to take another graft from another site, probably inferotemporal. Otherwise it could have been replaced with amniotic membrane graft to avoid excessive bare donor site, from patient's point of view. Size of graft was taken care of by accurate measurement using Vernier's caliper and taking 1-1.5 mm larger graft size to avoid size mismatch even if it retracts in size. Peribulbar block related complications, excessive bleeding, globe perforation, damage to extra-ocular muscles are few of major complications mentioned in literatures of pterygium surgeries are mostly technique related and can occur with any method of pterygium surgery. Thus, operative steps of both surgical methods are more or less equally safe. Subconjunctival haemorrhage was observed in 5 cases (20%) in group A and 3 cases (12%) of group B. We had done minimal use of cautery at recipient site for better graft take. Also in all cases, wherever subconjunctival haemorrhage occurred was at recipient site. So, incidence of subconjunctival haemorrhage may be partly due to vascularity of individual pterygium tissue and partly due to minimal use of cautery. In group A, immediate post operative graft edema was observed in 4 cases (16%) whereas no case of graft edema in group B was reported. This immediate post-operative complication was noted in few of group A patients only and these patients also complained more of subjective symptoms of watering and discomfort. This was for initial 5-7 days, which was taken care of by increasing frequency of topical steroids. After 7 days, there were no long term consequences of this complication in terms of signs or symptoms. Both groups had 2 cases (8%) each of foreign body granuloma, which required surgical removal of granuloma in operation theatre, but the graft was successfully preserved in all four cases. This complication was suture related and may be avoided by use of other modalities of putting graft like fibrin glue, autologous serum. In group A, 1 patient (4%) had graft infection, which was successfully managed by appropriate topical and systemic medications. There was no similar complication in group B. This can be attributed

to various factors like patient's conjunctival sac flora, subclinical conjunctivitis, intra-operative or post operative wound site contamination, non-compliance to post operative medications and other post op care; or it might be suggestive of increased susceptibility of conjunctival graft to infection. Though amniotic membrane grafts are very meticulously screened and processed before labelling safe for use, risk of contamination and infection cannot be completely ruled out in it too. No case of graft displacement, graft retraction, scleral / corneal thinning was noted in our study. Thus, there was no major complication in any of the patients in both the groups, either intraoperatively (globe perforation, damage to extra-ocular muscle) or postoperatively (graft displacement, graft retraction, post-operative sclera-corneal thinning). The various post operative complications seen in this study are minor ones. But there were no long term consequences of this complication in terms of signs or symptoms. So these both methods could be considered safe methods of pterygium treatment. In a study conducted by Ma D H, *et al*⁹, the authors had compared the surgical result of primary pterygium removal followed by amniotic membrane graft, conjunctival autograft and topical MMC treatment. They have shown that amniotic membrane graft was as effective as the other two methods, and as safe with no major complications. This suggests that amniotic membrane graft may be a preferred procedure for primary pterygium, and is especially suited for pterygium with diffuse conjunctival involvement or glaucoma patients waiting for filtering operations. Similar findings were also reported by Tananuvat N *et al*¹³ and Luanratanakorn P *et al*¹¹ in their study. In our study, we followed the definition of recurrence, as given by Sebban and Hirst¹⁴. There was recurrence of pterygium in 1 case each in both the groups. So, recurrence rate of pterygium by both the methods was 4%. Both cases of recurrence occurred around 3 months postoperatively. In both cases with recurrence of pterygium, the growth was seen underneath intact and in situ grafts; which might be suggestive of incomplete excision of primary pterygium. Sample size of our study was relatively small to firmly conclude about actual recurrence rate of surgical procedures. In a study by Ma D H *et al*⁹, 3.8% in the amniotic membrane graft group developed recurrence as compared to 5.4% in the conjunctival autograft group. Sharma A K, *et al*¹⁵ found recurrence rate of 2.6% in their study of conjunctival autografting. Katbaab A *et al*¹⁶ in their study on amniotic membrane grafting found the recurrence rate of 2% over a minimum follow-up period of 12 months. Thus our study was comparable with the above mentioned studies. In contrary to our findings Tananuvat N *et al*¹³ reported recurrence in 40.9% cases of

amniotic grafting group as compared to 4.76% in conjunctival grafting group. In a study by Luanratanakorn P, *et al*¹¹ after surgery for primary pterygium, the recurrence was observed in 12.3% eyes with conjunctival grafting and 25% eyes with amniotic membrane grafting, at the end of 6 months. There was no major complication in any of the patients in both the groups, either intraoperatively (globe perforation, damage to extra-ocular muscle) or postoperatively (graft displacement, graft retraction, post-operative sclera-corneal thinning). Both, amniotic grafting and conjunctival autografting are equally safe and effective procedures in the management of primary pterygium with low recurrence rate. Conjunctival autografting, being "autograft," has no issues of availability and extra cost. But patients may have slight discomfort in immediate post operative period owing to exposed donor site. Amniotic membrane grafting is especially useful in patients with diffuse ocular surface disorders and patients requiring large graft size. The superior conjunctiva is salvaged in this procedure can be useful if patient requires glaucoma surgery in future. However, availability and cost may limit use of amniotic membrane.

CONCLUSION

Thus from the above discussion we conclude that both amniotic membrane grafting and conjunctival autografting are equally safe and effective procedures for the management of primary pterygium. And Amniotic membrane grafting is viable alternative to conjunctival autografting.

REFERENCES

1. Sihota R, Tandon R. Parson' Diseases of the Eye, Elsevier Pub. 21st ed.,2011:181-182
2. Dutta L C, Dutta N K. Modern Ophthalmology, Jaypee Brothers Medical Publisher, New Delhi 3rd ed. 2009: vol1:127-128
3. Yanoff and Duker. Ophthalmology, 3rd ed.: 248
4. Sandeep Saxena. Clinical Ophthalmology Medical And surgical Approach. Jaypee highlights 2nd ed
5. Varssano D, Michaeli-Cohen A, Loewenstein A. Excision of Pterygium and Conjunctival Autograft. IMAJ 2002; 4:1097-1100.
6. Rao SK, Lekha T, Mukesh BN, Sitalakshmi G, Padmanabhan P. Conjunctival-Limbal autografts for primary and recurrent Pterygia: Technique and results. Indian J Ophthalmol 1998;46:203-9
7. Shrestha A, Shrestha A, Bhandari S, Maharajan N, Pant S R, Pant B P. Inferior conjunctival autografting for pterygium surgery: an alternative way of preserving the glaucoma filtration site in far western Nepal. Clin Ophthalmol. 2012; 6: 315–319.
8. Cameron. Pterygium throughout world. Brit. J. Ophthalm 1965
9. Ma D H, See L C, Liao S B, Tsai R J. Amniotic

- membrane graft for primary pterygium: comparison with conjunctival autograft and topical mitomycin C treatment. *Br J Ophthalmol* 2000;84:973–978
10. Lu P, Chen X M. Prevalence and risk factors of pterygium. *Int J Ophthalmol*, Vol.2, No.1, Mar.18, 2009: 81-85.
 11. Luanratanakorn P, Ratanapakorn T, Suwan-apichon O, Chuck R S. Randomised controlled study of conjunctival autograft versus amniotic membrane graft in pterygium excision. *Br. J. Ophthalmol.* 2006;90;1476- 1480
 12. Maheshwari S. Effect of pterygium excision on pterygium induced astigmatism. *Indian J Ophthalmol* 2003;51:187-8
 13. Tananuvat N, Martin T. The results of amniotic membrane transplantation for primary pterygium compared with conjunctival autograft. *Cornea.* 2004; 23:458–463.
 14. Sebban A, Hirst LW. Pterygium recurrence rate at The Princess Alexandra Hospital. *Aust N Z J Ophthalmol.* 1991; 19:203–206.
 15. Sharma A K, Wali V, Pandita A. Corneo- Conjunctival Auto Grafting in Pterygium Surgery. *J K science.* Vol. 6 No. 3, July-September 2004
 16. Katbaab A, Ardekani A, Khoshniyat H, Hosseini H J. Amniotic Membrane Transplantation for Primary Pterygium Surgery. *J Ophthalmic Vis Res* 2008; 3 (1): 23-27.

Source of Support: None Declared
Conflict of Interest: None Declared