

Sturge- weber syndrome: case report with ophthalmic manifestations

U. S. Mohite¹, Mahesh Thikekar^{2*}, K. R. Jadhav³

¹HOD, ²Sr. Resident, ³Medical Officer, Department of Ophthalmology, Government Medical College, Latur, Maharashtra, INDIA.

Email: drmahesh.tikekar@gmail.com

Abstract

Sturge Weber Syndrome sometimes referred to as encephalotrigeminal angiomas, is rare phakomatosis consisting neurological, skin, ocular manifestation. Ophthalmological features of this disease can vary greatly most relevant characteristic is represented by the glaucoma and is associated with vascular malformations of conjunctiva, episclera, choroid and retina. The goal of present paper is to report a case of 17 yrs old male patient with Sturge Weber Syndrome presenting its inherent clinical features and to underline the importance of its diagnosis in the clinical ophthalmological practice.

Keywords: SWS, Glaucoma, Choroidal hemangioma, naevus flammus.

*Address for Correspondence:

Dr. Mahesh Thikekar, Sr. Resident, Department of Ophthalmology, Government Medical College, Latur, Maharashtra, INDIA.

Email: drmahesh.tikekar@gmail.com

Received Date: 28/02/2015 Revised Date: 20/12/2015 Accepted Date: 14/10/2016

Access this article online

Quick Response Code:	Website: www.medpulse.in
	DOI: ---

INTRODUCTION

Sturge Weber Syndrome was first described by Schimer in 1860 and later more specifically by Sturge (1879) and Weber (1929) which resulted in classic definition. It is believed that it is caused by the abnormal persistence of an embryonal vascular system which is localized around the cephalic region the neural tube (AYDIN *et al*, 2000) Patients affected by SWS present congenital dermal capillary malformation of the face, know as port-wine or flammeus nevus. The most common ocular manifestation represented by the glaucoma and is associated with vascular malformations of conjunctiva, episclera, choroid and retina. In this paper is reported a case of a patient affected by SWS presenting its inherent clinical features. It is emphasized the importance of an accurate diagnosis and management in the clinical ophthalmological practice.

CASE REPORT

A 17 yrs old male patient presented with parents to ophthalmology OPD, of GMC Latur with complains of diminision of vision in the left eye, ocular pain in the left eye and headache since childhood.

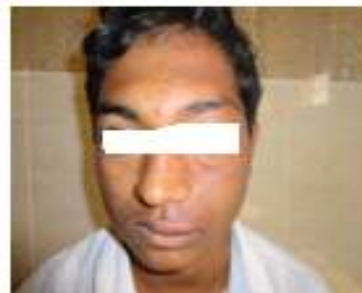

Figure 1:

Physical examination revealed reddish discolouration in complete left half of face (naevus flammus) and mild proptosis in left eye. On detailed ophthalmological examination- In the right eye vision was 6/6, IOP- WNL, Anterior chamber –normal depth and fundus examination- WNL. In the left eye vision was no PL, IOP -24mm of Hg, anterior chamber – normal depth with iridocorneal angle open, fundus examination shows –left eye media hazy, optic disc oedema, serous detachment (inferiorly), chorio retinal atrophic patches in superior quadrant, sclerosed blood vessels in periphery.

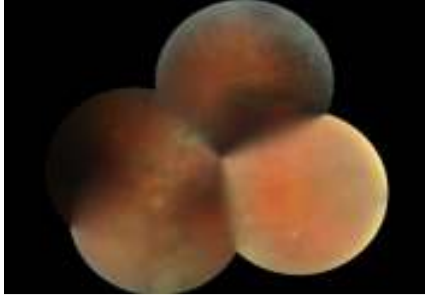


Figure 2: Fundus Photograph Of left eye

When asked in details to parents patient was having history of convulsions and right sided weakness since birth. Patient was on regular anticonvulsant treatment. No history of mental retardation, parent also reported that unilateral Port Wine stain in left half of face (naevus flammeus) was present since birth however the stain spontaneously became faint. Computerised Tomography has been performed - CT axial images show dense gyriform calcification in the left posterior parietal and occipital region along with left cerebral hemi atrophy and calvarial thickening.

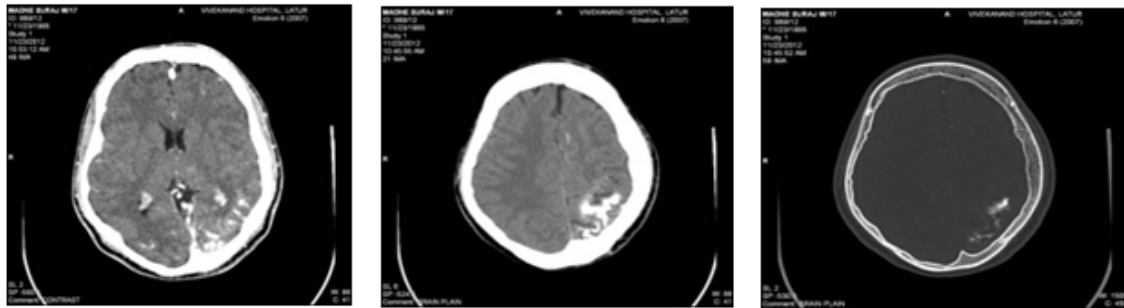

Figure 3: CT brain

CT axial sections of orbit shows dense homogenous enhancement along posterior wall on contrast study suggestive of choroidal haemangioma.

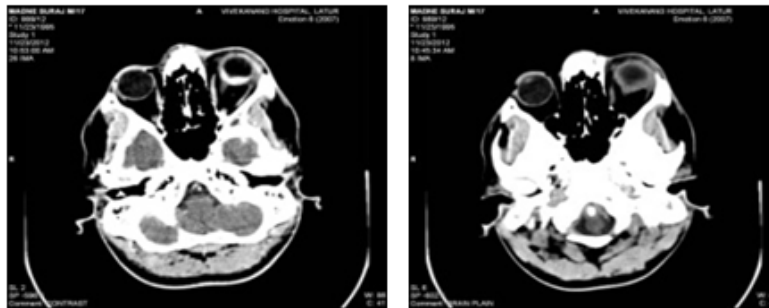


Figure 4: CT orbit

USG B Scan of left eye has been performed shows- gross chorio retinal thickening approx ___ mm. Incomplete posterior vitreous detachment with inferior retinal detachment, occasional vitreous debris, axial length = 24.14 mm

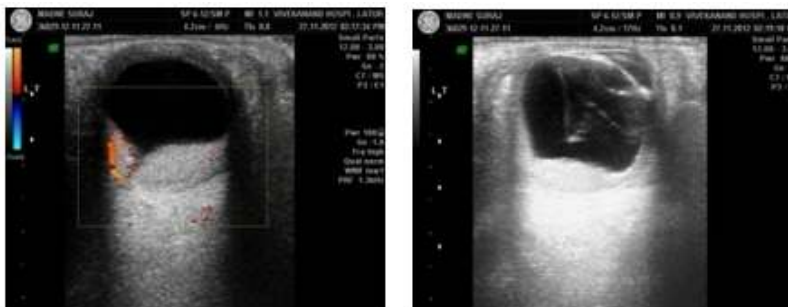


Figure 4: USG B- Scan left eye

DISCUSSION

SWS has extremely varied clinical features and it can be characterised by Port Wine stain in the face, leptomenigeal angioams, ipsilateral gyriform calcifications, convulsive crisis, varied forms of ocular involvement, hemiparesis. The encephalotrigeminal angiomas has been classified in three types

- Type 1: Characterised by facial and leptomenigeal and possibly glaucoma.
- Type 2: In which detected facial angioams without neurological disturbances.
- Type 3: That is represented by the presence of leptomenigeal angioams (AYDIN *et al*,2001;Girija and Somnath,2002).

This is a case report of young patient who has type 1 of SWS according to above classification. Anderson's rule says that when nevus flammeus involves the upper lid, there is ipsilateral intraocular involvement. In 2/3 of patients who developed glaucoma, the clinical features resemble those of congenital buphthalmos, however late onset glaucoma occurring in adolescence or young adult life may resemble primary open angle glaucoma. The following etiological explanation for the glaucoma have been advocated a) Mechanical theory- developmental anomalies of anterior chamber angle may cause an increased resistance to aqueous outflow.b)vascular theory-glaucoma, due to presence of vascular malformations that might increase production, decrease out flow or actually change components of aqueous fluid or interfere with extracular drainage. Elsching suggested that, because of frequent occurrence of choroidal angioams and increase permeability of uveal vessels may be responsible for hypersecretion of aqueous (plethoric glaucoma). Choroidal haemangioma are reported in approximately 40 % patients with SWS. Haemangioma

can cause secondary serous retinal detachment and cystoid degeneration. Exudative detachment may lead to secondary glaucoma and blindness. Other rare ophthalmological manifestations include ipsilateral hyperchromia of iris, spontaneous dislocation of lens. Conjunctival and episcleral vascular lesions, megalocornea in the absence of glaucoma. Neurological deficit is caused by the intracranial vessel malformations.

CONCLUSION

The great frequency of ocular manifestations of SWS patients demands the ophthalmological knowledge of this syndrome signs and symptoms as well as knowledge of the best treatment to avoid complications it is important to note the necessity of a multidisciplinary team to perform a proper treatment and preventive following up of these patients.

REFERENCES

1. Weiss JS and Ritch R. Glaucoma in the phacomatosis In Ritch R, Shields B, Kurpin T (Eds). Glaucomas. St. Louis: The CV Mosby company 1989; 905-29.
2. Thomas-Sohl KA, Vaslov DF, Maria BL: SWS: review. *Pediatr Neurol* 2004;30:303-10.
3. Griffiths PD: SWS revisited: the role of neuroradiology. *Neuropediatrics* 1996, 27:284-294.
4. Girija AS, somnath V.A. case of hemiplegic migraine with leptomenigeal angiomas. *Neurol India* 2002; 50:522-523.
5. Sujansky and Conradi, "outcome of SWS in 52 adults" *American Journal of Medical genetics* 57:35-45(1995).
6. L.C. Dutta, Nitin K Dutta, MODERN OPHTHALMOLOGY, 3rd Edition, JAYPEE brothers Medical Publishers (P) LTD. New Delhi; Vol. 2, page No. 667-668.

Source of Support: None Declared
Conflict of Interest: None Declared