Original Research Article

Clinical study on external vs endoscopic dacryocystorhinostomy

Badrinath Talwar

Assistant Professor, Department of Ophthalmology, Kanachur Institute of Medical Sciences, Mangalore, INDIA.

Abstract

Background: Chronic Dacryocystitis is an inflammatory condition of the lacrimal sac most commonly associated with partial or complete obstruction of the nasolacrimal duct. It usually presents with watering and sometimes purulent discharge, but some may progress and cause severe ocular and extra ocular complications.

Keywords: Lacrimal Duct, Endoscopic, Endonasal, Epiphora.

***Address for Correspondence:**
Dr Badrinath Talwar, Assistant Professor, Department of Ophthalmology, Kanachur Institute of Medical Sciences, Mangalore, INDIA.
Email: badrikanachurophthal@gmail.com

Received Date: 04/10/2017 Revised Date: 16/11/2017 Accepted Date: 25/12/2017

Access this article online	
Quick Response Code:	Website: www.medpulse.in
	DOI: https://doi.org/10.26611/1002435

INTRODUCTION

It is thought that partial nasolacrimal duct obstructions (NDOs) are associated with generally unpredictable surgical outcomes as compared with total blocks when using external dacryocystorhinostomy (ext-DCR) and silicone tube intubation.[1,2,3,4,5] EES-DCR is an acceptable surgical option for the management of partial NDO, though the success rate is nevertheless higher in ext-DCR compared with EES-DCR. The subjective results agreed strongly with objective findings. On the basis of subjective criteria, this trial shows a successful outcome of 86% with EES-DCR and 100% with ext-DCR. Three patients with EES-DCR surgery had failed surgery—irrigation was blocked and the rhinostomy either scarred or occluded by a large granuloma. This represents either a progression of their disease or an iatrogenic obstruction. External dacryocystorhinostomy is used in various forms to treat NDO for over 100 years.[6,7] In comparison, EES-DCR is much more recent,[8] interest in it being re-kindled because of advances in instrumentation, notably the introduction of the rigid nasoendoscope, FESS, and laser surgery.[9] Ext-DCR is still regarded as the gold standard in terms of functional outcome.[10] For example, a large study of patients with complete NDO by Dolman,[11] compared the outcome of 153 ext-DCR (90.2% success) with 201 EES-DCR (89.1% success). There was no statistically significant difference between these two approaches.[11] Several surgeons have found distinct advantages of the endonasal route, that is, the surgery was faster and is preferred by certain patients.[11] EES-DCR has advantages, which are of special relevance to many patients with partial NDO, who owing to troublesome, but often inconstant, symptoms may be less likely to be offered or to accept ext-DCR.[1, 5] These include the avoidance of a skin incision, which is of cosmetic importance to certain patient groups, such as young patients,[12,13] to those with dark skin prone to keloid formation,[24] as well as patients with a flat nasal bridge.[24] In addition, EES-DCR avoids damage to the medial canthal tendon and the potential of a medial canthal deformity. Surgery is more likely to be performed as a day-case, but the results in the literature tend not to be as good as ext-DCR, presumably as a smaller rhinostomy has traditionally been created by most surgeons who perform the procedure, though this practice varies between units.[14]

Objectives: To compare the study subjects and the outcomes between the *External vs Endoscopic Dacryocystorhinostomy.*

METHODOLOGY

The present study was a retrospective, observational, nonrandomized, comparative clinical study done by Reviewed medical records of 48patients who underwent DCR at Kanachur Institute of Medical Sciences, Mangalore. Data regarding the intra-operative course, surgical outcomes, and postoperative complications were analyzed. Anatomical success was defined as patency confirmed by intranasal endoscopic inspection of the

How to cite this article: Badrinath Talwar. Clinical study on external vs endoscopic dacryocystorhinostomy. *MedPulse International Journal of Ophthalmology.* December 2017; 4(3): 66-68. https://www.medpulse.in/Ophthlmology/

ostium and successful lacrimal sac syringing whereas functional success was defined as complete resolution of epiphora assessed and documented post-operatively. In our institute the Departments of Ophthalmology and Otorhinolaryngology assessed the patients requiring DCR and suggested the patients to undergo External DCR or Endonasal based on the clinical examination findings, the co-morbidities and general condition of the patients. Our patients were evaluated initially with a thorough history. The time of onset, laterality and type of discharge was noted.

History of prior facial trauma, orbital radiation, use of ophthalmic medications, nasal allergies and any prior intranasal surgeries undertaken was noted.

On examination 2 important tests were performed followed by Endoscopic Nasal Examination[6]

1. ROPLAS (Regurgitation On Pressure over the Lacrimal Sac area)

A firm pressure was applied over the sac area and noted for any regurgitation. Any regurgitation of fluid was considered as ROPLAS positive and no regurgitation was considered as ROPLAS negative. When positive, the type of regurgitate was noted-watery, mucoid, mucopurulent or blood-stained. Clear watery fluid is seen in atonic sac. Reflux of mucoid or mucopurulent material is indicative of NLDO. Blood-stained discharge is seen in malignancy or dacryolith.

2. LACRIMAL SAC SYRINGING

Lacrimal sac syringing is the most important procedure in the evaluation of epiphora. Lacrimal irrigation was performed with the patient reclining in the examination chair. The conjunctiva is anaesthetized with topical anaesthetic drops. A 2 cc syringe filled with sterile water is flushed from lower punctum and patiernt is asked to raise his/her hand if he/she feels it in his/her nose/throat. This procedure was later repeated on the upper punctum and same to be followed in the opposite eye.

Endoscopic Nasal Examination:

A good nasal examination was performed to rule out the common nasal conditions which cause epiphora, as also impede the success of a good surgery. The commonly used nasal endoscope for the diagnostic office procedure is a 2.7 mm, 30° endoscope. This provides a good view of the lateral nasal wall. Presence of any nasal pathology including nasal polyps and anatomical variation of nasal structures were documented.

Following this a decision was made to take up the patient for Endoscopic Endonasal DCR or External DCR.

All patients undergoing Endonasal DCR were given General Anesthesia, however all the External DCRs was performed under Local Anesthesia. A standard procedure was followed for external DCR which was performed without stenting except in revision cases where stents were used. There are different techniques of performing Endonasal DCR.

RESULTS

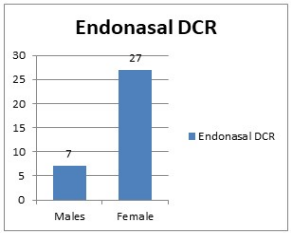

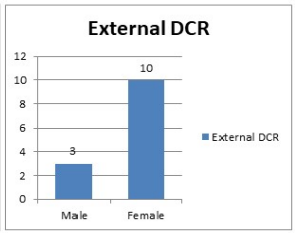

Figure 1

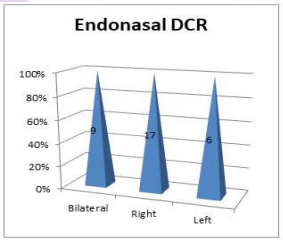

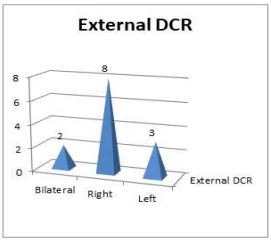

Figure 2

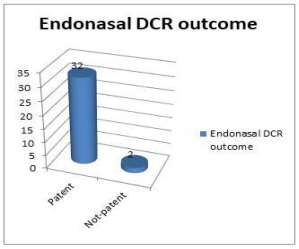

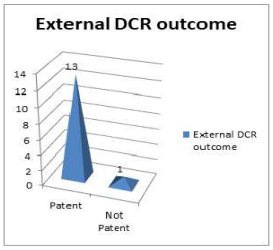

Figure 3

Figure 1: Comparison of Gender distribution among subjects in both the groups; **Figure 2:** Comparison of Side distribution among subjects in both the groups; **Figure 3:** Comparison of Outcome among subjects in both the groups.

DISCUSSION

It was seen in our study that most patients undergoing DCR for Primary acquired nasolacrimal duct obstruction (PANLDO) were females, with F:M ratio – 4:1 This is in concurrence with other studies which state the occurrence of Primary acquired NLDO to be more commonly seen in females. Primary acquired nasolacrimal duct obstruction (NLDO) is a common cause of epiphora in adults, and it is

4-5 times more common in females. Also, it was seen in our study that most patients presenting with chronic Dacryocystitis had disease on the Right side. As our sample size is low, it is to be ascertained whether this is an incidental finding or if there is something scientific influencing the occurrence of this disease more commonly on the right side. Of the 48 cases, 47 were primary cases and 1 case was a revision External DCR and only in this patient stent was placed and in all other cases in both Endoscopic and External DCR we have not used stents. In the course of the surgery we have noted that patients who presented with unilateral disease had a significant nasal septal deviation towards the side of the pathology especially around the region of the nasolacrimal duct, that is, anterior to the axilla of the middle turbinate. Both External and Endonasal DCR had comparable outcomes. In the Endonasal DCR group it was seen that out of the 34 patients operated, 2 patients had continued epiphora. Thus the success rate stands at 94%. It was noted that both patients who continued to have epiphora after Endonasal DCR had lot of pus in the nasolacrimal apparatus with thick sac wall noted intraoperatively. Though the patients were rid of the purulent discharge post-operatively they continued to have epiphora. One of these patients underwent a revision external DCR with stenting which was done at our institute itself, following which she was rid of her symptoms. Endoscopic evaluation of this patient postoperatively showed excessive growth of nasal mucosa blocking the fistula created surgically. In the External DCR group, out of the 14 patients operated one patient had epiphora post-surgery(93%). This patient had developed an abscess that had opened out on to the skin pre-operatively. Also healing of the incision wound post-operatively was delayed in this patient. In the Endonasal DCR group post-operative complications noted include nasal stuffiness noted in few patients which resolved within 15days. The intra-operative course largely dictates the immediate post-operative outcomes. The patients who had nasal stuffiness had surgical duration of more than 30minutes. All patients in whom Endonasal DCR was performed in around 30minutes were extremely comfortable in the immediate post-operative period. The surgical duration was largely dependent on the time required to punch out the bone, and the infection status of the Nasolacrimal apparatus. It was noted that in young male patients the bone was considerably thick which prolonged the intra-operative course. Patients who had sacs filled with purulent content had associated increased bleeding noted intra-operatively which prolonged the intra-operative course.2 patients had bleeding from the nose with lasted for 2 days post-operatively and it was minimal. It was treated by nasal decongestants drops. In the External DCR group, bleeding was of concern in 5 patients intra-operatively, all of whom had infected sacs with purulent content.

CONCLUSION

We conclude that detailed examination and appropriate selection of patients with meticulous surgical technique is what gives good results in Dacryocystorhinostomy, be it Endoscopic or External.

REFERENCES

1. Chung YA, Yoo IeR, Oum JS, Kim SH, Sohn HS, Chung SK. The clinical value of dacryoscintigraphy in the selection of surgical approach for patients with functional lacrimal duct obstruction. Ann Nucl Med. 2005;19:479–483.
2. Bleyen I, Paridaens AD. Bicanalicular silicone intubation in acquired partial nasolacrimal duct obstruction. Bull Soc Belge Ophtalmol. 2008;309-310:23–26.
3. Sahlin S, Rose GE. Lacrimal drainage capacity and symptomatic improvement after dacryocystorhinostomy in adults presenting with patent lacrimal drainage systems. Orbit. 2001;20:173–179.
4. O'Donnell B, Shah R. Dacryocystorhinostomy for epiphora in the presence of a patent lacrimal system. Clin Experiment Ophthalmol. 2001;29:27–29.
5. Delaney YM, Khooshabeh R. External dacryocystorhinostomy for the treatment of acquired partial nasolacrimal obstruction in adults. Br J Ophthalmol. 2002;86:533–535.
6. Toti A. Nuovo metodo conservatore di cura radicale delle suppurazioni croniche del sacco lacrimale (Dacriocistorinostomia) L Clin Mod. 1904;10:385–387. [Google Scholar]
7. Caldwell GW. Two new operations for obstruction of the nasal duct, with preservation of the canaliculi, and an incidental description of a new lacrymal probe. NY Med J. 1893;57:581–582. [Google Scholar]
8. Jokinen K, Karja J. Endonasal dacryocystorhinostomy. Arch Otolaryngol. 1974;100:41–44. [PubMed] [Google Scholar]
9. Massaro BM, Gonnering RS, Harris GJ. Endonasal laser dacryocystorhinostomy. a new approach to nasolacrimal duct obstruction. Arch Ophthalmol. 1990;108:1172–1176.
10. Metson R, Woog JJ, Puliafito CA. Endoscopic laser dacryocystorhinostomy. Laryngoscope. 1994;104:269–274.
11. Woog JJ, Metson R, Puliafito CA. Holmium:YAG endonasal laser dacryocystorhinostomy. Am J Ophthalmol. 1993;116:1–10.
12. Tsirbas A, Wormald PJ. Mechanical endonasal dacryocystorhinostomy with mucosal flaps. Br J Ophthalmol. 2003;87:43–47.
13. Dolman PJ. Comparison of external dacryocystorhinostomy with nonlaser endonasal dacryocystorhinostomy. Ophthalmology. 2003;110:78–84.
14. Hartikainen J, Antila J, Varpula M, Puukka P, Seppä H, Grénman R. Prospective randomized comparison of endonasal endoscopic dacryocystorhinostomy and external dacryocystorhinostomy. Laryngoscope. 1998;108:1861–1866

Source of Support: None Declared
Conflict of Interest: None Declared