Original Research Article

Clinical study of ophthalmological manifestations in HIV positive patients attending tertiary care hospital

U S Mohite[1], Sayed Ashfaq[2*]

[1]Professor and HOD, [2]Junior Resident, Department of Ophthalmology, Government Medical College, Latur, Maharashtra, INDIA.
Email: drsayedashfaque@rediffmail.com

Abstract

Background: HIV causes a wide spectrum of diseases and it is a multisystem disorder. The ophthalmic disease does affect 70-80% of the patients with HIV infection. Ocular manifestations may be the initial presentation of a systemic infection in an asymptomatic HIV positive patient. **Aim:** To study the ophthalmological manifestations in HIV positive patients attending tertiary care hospital. **Material and Methods:** All 120 cases of HIV infected and AIDS patients on HAART were included in the study. Detailed history and examination of the eye (adnexae with extraocular structures, anterior and posterior segment, visual acuity) was undertaken along with routine laboratory investigations. **Results:** The estimated prevalence of ophthalmic manifestations associated with HIV infection was found to be 40.83%. Adnexal manifestations were found in 10.8% patients. Most common being conjunctival microvasculopathy in 4.2% patients. Anterior segment manifestations were found in 13.3% patients. Most common being keratoconjunctivitis sicca in 5.8% patients. Posterior segment manifestations were found in 11.7 % patients. Most common being HIV retinopathy in 9.2% patients. Neuro-ophthalmological manifestations were found in 4.2% patients. Most common being optic atrophy in 1.7% patients. **Conclusion:** The prevalence of ocular manifestations in our study was higher and most of the ocular manifestations were asymptomatic. Our study highlights the need for a routine ophthalmological screening of all HIV seropositive patients regardless of their immune status.

Key Word: HIV infection, AIDS, ocular manifestations, HIV retinopathy

***Address for Correspondence:**
Dr. Sayed Ashfaq, Junior Resident, Department of Ophthalmology, Government Medical College, Latur, Maharashtra, INDIA.
Email: drsayedashfaque@rediffmail.com
Received Date: 23/12/2018 Revised Date: 16/01/2019 Accepted Date: 10/02/2019
DOI: https://doi.org/10.26611/1009924

Access this article online	
Quick Response Code:	Website: www.medpulse.in
	Accessed Date: 13 February 2019

INTRODUCTION

The Human Immunodeficiency Virus (HIV) / Acquired Immunodeficiency Syndrome (AIDS) is one of the most feared infectious diseases of the late 20th century. India has a large number of patients with AIDS, which is the third largest population of this group in the world.[1] HIV causes a wide spectrum of diseases and it is undoubtedly a multisystem disorder, but the ophthalmic disease does affect 70-80% of the patients with HIV infection sometime during the natural history of their infection. Various studies have demonstrated that 40-45% of the HIV infected patients do have some or the other ophthalmic manifestations when they are examined by an ophthalmologist.[2] The spectrum of the HIV associated ophthalmic disease is very broad and it ranges from adnexal disorders to posterior segment disorders, including the optic nerve and the optic tract. These ocular manifestations can be the presenting signs of a systemic infection in an otherwise asymptomatic individual. The sequelae of HIV infection increase as immunocompetency decreases. While the asymptomatic ocular lesions occur in the earlier stages, the relentless destructive and blinding infections, especially the opportunistic ones occur in the later stages of the disease. However, introduction of Highly Active Anti-Retroviral therapy (HAART) has reduced the risk of mortality and

How to cite this article: U S Mohite, Sayed Ashfaq. Clinical study of ophthalmological manifestations in HIV positive patients attending tertiary care hospital. *MedPulse International Journal of Ophthalmology.* February 2019; 9(2): 31-35.
https://www.medpulse.in/Ophthlmology/

opportunistic infections in AIDS. Ocular manifestations may be the initial presentation of a systemic infection in an asymptomatic HIV positive patient. Hence, early detection of the manifestations is critical which has got an impact on the prognosis of the disease. The present clinical study was conducted to study the ophthalmological manifestations in HIV positive patients attending tertiary care hospital.

MATERIAL AND METHODS

This cross sectional study was based on the patients with HIV infection/AIDS, who were referred to the Ophthalmic OPD. These patients were referred from the District ART Centre for a complete ophthalmic evaluation, irrespective of their immune status and the presence or absence of symptoms. All the patients underwent a complete ophthalmic examination, which included both anterior and posterior segment evaluation and colour vision assessment.

Sample size: All cases of HIV infected and AIDS patients on HAART attending the outpatient department of ophthalmology were selected for the study.

Inclusion criteria

- HIV-positive patients registered at the ART centre.
- Patients referred to Ophthalmology OPD for ocular complaints.

Exclusion criteria

- Patients who were non-compliant.
- Patients with similar ocular manifestations secondary to immunosuppression due to other causes.
- Patients who were non HIV infected.
- Patients with HIV with pre-existing ocular disease.
- Patients with HIV developing ocular disease unrelated to the disease under study like traumatic corneal ulcer.

Patient evaluation: Each patient subjected to detailed history taking regarding the symptoms and duration of the disease. A careful and detailed examination of the eye was undertaken including:

- Examination of adnexae and extraocular structures included the examination of face, orbits, eyebrows, eyelids, palpebral fissure, extraocular movements and lacrimal sac.
- Examination of anterior segment was done in detail by slit lamp biomicroscopy.
- Examination of posterior segment was done by ophthalmoscopy including direct and indirect ophthalmoscopy and + 90D biomicroscopy.
- Recording of visual acuity and intraocular pressure was done.

  Routine laboratory investigation like complete haemogram, serum creatinine, blood urea, serum bilirubin, blood sugar, VDRL were done.

RESULTS

This study was carried out on 240 eyes of 120 patients in Department of Ophthalmology of a Tertiary Care Hospital. Males constituting 76 (63.3%) while females constituting 44 (36.7%) of the cases. Male to female ratio was 1.724:1. Out of 76 males, ocular manifestations were found in 29 males and ocular manifestations were absent in 47 males. Out of 44 females, ocular manifestations were found in 20 females and ocular manifestations were absent in 24 females (p value 0.5545). The mean age of patients was range 4- years with 9.2% patients in age group <20 years, 25% patients in age group of 21-30 years, 35% patients in age group of 31-40 years, 13.3% patients in age group of 41-50 years and 13% patients in age group of >50 years. More than half (60%) of the patients belonged to the age group of 21-40 years (p value 0.6776).60% of the patients were married, 27% patients were single, 10% patients were divorced and 3% widowed.78.3% of the patient's occupation were unskilled. 17.5% were skilled, and 4.2% were unemployed. Schirmer's test results showed presence of dry eye in 5.8% patients and test results were normal in 94.2% patients (p value 0.00391). In 43.3% patients the duration of the illness was <1 year, in 28.3% patients the duration was between 1 to 5 years, in 19.2% patients the duration was between 6 to 10 years and in 9.2% patients the duration was >10 years (p value 0.0001). 48.3% patients were having CD4 count of >500/mm^3, 42.5% patients had CD4 count between 201-500/mm^3 and 9.2% patients had CD4 count <200/mm^3 (p value 0.0000).48.3% patients were in WHO clinical stage I of the disease, 25% were in stage II,20% were in stage III and 6.7% in stage IV.

Table 1: HIV disease characteristics in study population

HIV disease characteristics	Without ocular manifestations	With ocular manifestations
Duration of the HIV since diagnosis		
<1 years	41	11
1-5 years	20	14
6-10 years	08	15
>10 years	02	09
CD4 count		
<200	02	09
201-500	17	34
>500	52	06
Clinical stage of HIV		
Stage I	52	06
Stage II	15	15
Stage III	03	21
Stage IV	01	07

Table 2: Distribution according to the types of ocular symptoms

Ocular symptoms	Without ocular manifestations	With ocular manifestations	Total
diminution of vision	0	12	12 (7.9%)
Redness	4	9	13 (8.6%)
Irritation and FB sensation	5	18	23 (15.2%)
Photophobia	0	10	10 (6.6%)
Floaters	0	1	1 (0.7%)
Others	3	4	7 (4.6%)
No symptoms	59	26	85 (56.3%)
Total	**71**	**80**	**151 (100%)**

Visual acuity of 117 (97.5%) patients were within normal range, one (0.8%) patient had visual impairment and 2 (1.7%) patients were blind, one was blind due to POAG which is not a manifestation related to HIV infection (p value 0.1076).19.2% patients had ocular symptoms out of which 15.8% patients had more than one symptom. Most common symptom encountered was irritation and foreign body sensation in 15% patients.

Table 3: Ocular manifestations in study population

Ocular manifestations found	No. of patients	Percentage
Adnexa	**13**	**10.8**
Blepharitis	03	2.5
Molluscum contagiosum	01	0.8
Conjunctival microvasculopathy	05	4.2
Herpes zoster ophthalmicus	02	1.7
Ocular surface squamous neoplasia	02	1.7
Anterior segment	**17**	**14.2**
Complicated cataract	01	0.8
Keratoconjunctivitis sicca	07	5.8
Infectious keratitis	04	3.3
Iridocyclitis	04	3.3
Episcleritis	01	0.8
Posterior segment	**14**	**11.7**
HIV retinopathy	11	9.2
CMV retinitis	02	1.7
BRVO	01	0.8
Neuro-ophthalmological	**05**	**4.2**
Cranial nerve palsy	01	0.8
Optic neuritis	01	0.8
Optic atrophy	02	1.7
Papilloedema	01	0.8
Total	**49**	**40.8**

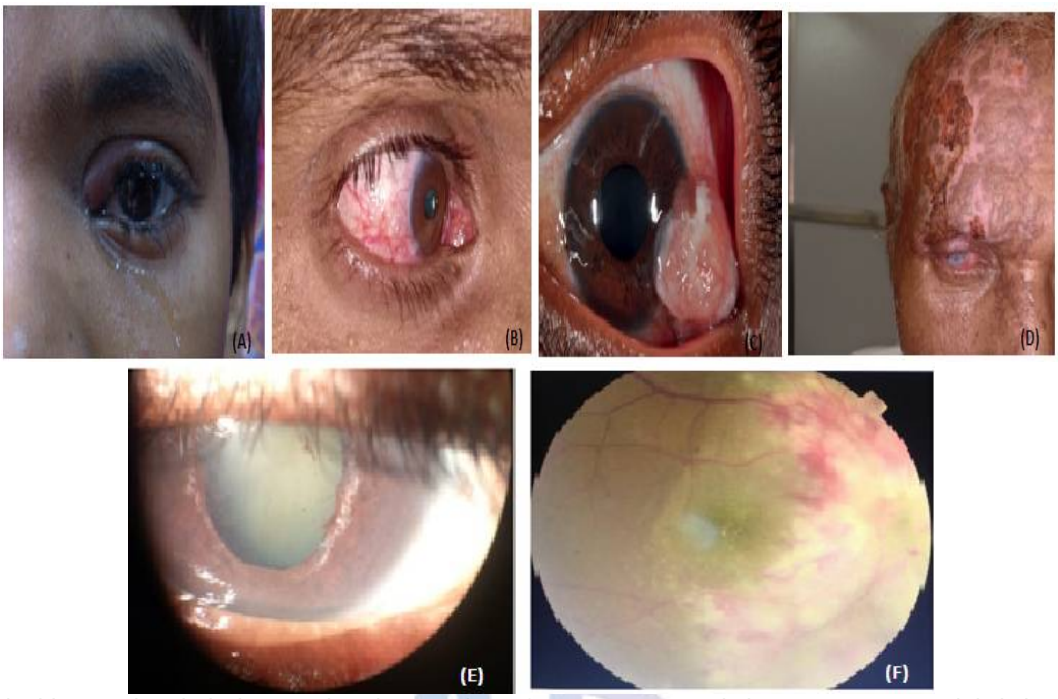

Figure: A: Blepheritis **B:** Conjunctival microvasculopathy **C:** Ocular surface squamous neoplasia **D:** Herpes zoster ophthalmicus **E:**Chronic iridocyclitis **F:** CMV retinitis

DISCUSSION

The estimated prevalence of ophthalmic manifestations associated with HIV infection in our study was found to be 40.83%, which is similar to the study done by Aacharya et al (37.6%).[3] According to a study done by Sudharshan et al, the prevalence of ophthalmic manifestations was found to be 68.5.[4] The prevalence of ocular manifestations among patients with current CD4 count of >500/mm^3 was 10.3%, among patients with current CD4 count of 201-500/mm^3 was 66.7% and among patients with current CD4 count of <200/mm^3 was 81.2%. The prevalence of ocular manifestations increased with decrease in the CD4 count of the patients. There was significant association between the prevalence of ocular manifestations and current CD4 count of the patients (p value=0.0000). In the study by Pathai et al, the prevalence of ophthalmic manifestations in patients with CD4 count less than 200 cells/mm^3 was 23.8%.[5] Highest prevalence of ocular manifestations were found in patients with stage III and IV disease (87.5%) followed by patients in stage II (50%). The least prevalence was noted in stage I (10.3%). This relation was statistically significant (P=0.0000) and suggests that the magnitude of the ocular involvement increases with severity of the HIV/AIDS disease. The high magnitude of ocular manifestations in stage I demonstrates that ocular manifestations may occur at any CD4 count. Most of the manifestations in this stage were non-blinding. There was significant association found between presence of ocular symptoms and the occurrence of ocular manifestations. (P=0.0000). Among the 120 patients, 117 patients had visual acuity within normal range, one patient had visual impairment and one patient was blind. Hence, the prevalence of visual impairment due to HIV associated ocular manifestation was around 1.7%. Visual impairment was more common in patients with posterior segment involvement. In our study, the prevalence of posterior segment manifestations (11.7%) were less than anterior segment manifestations (14.2%). Whereas in the studies done by Narwade et al[6] and Sudharshan et al[7] it was found that posterior segment manifestations were more common than anterior segment manifestations. Prevalence of posterior segment manifestations found in our study was comparable to the study done by Ushalatha et al.[8] Among the manifestations HIV retinopathy (9.2%) was most common in our study which is similar to the study done by Narwade et al[6] and Aacharya et al.[3] A majority of these patients presented with a single cotton wool spot in one eye. In the study done by Sudharshan et al,[7]CMV retinitis was the most common manifestation followed by HIV retinopathy. This can be related to the fact that in our study the mean CD4 count was greater than 100/mm^3 as all the patients were examined at the early stages of HIV infection, whereas in their study prior to enrollment in ART center screening was done. The median range of CD4 count in our study is around 300 cells/mm^3. The most common

opportunistic infection was CMV retinitis which was seen in 2 patients (1.7%). CMV retinitis was noted only in patients with a CD4 count of less than 200 while the HIV microangiopathy was noted in patients with any range of CD4 counts.Superotemporal BRVO was seen in 1 patient(0.8%). Ocular TB, endophthalmitis, vitritis and chorioretinitis (active/ healed) were not recorded in our study. In our study, the anterior segment manifestations were found in 17 patients (prevalence about 14.2%).Most common anterior segment manifestation was found to bekeratoconjunctivitis sicca (dry eyes) (5.8%) which was seen in 7 patients, followed by infectious keratitis and iridocyclitis which was seen in 4 patients each (3.3%), complicated cataract was seen in one patient (0.8%) and Episcleritis(0.8%) in one patient. Comparing to the studies by Narwade et al[6] and Sudharshan et al,[7] we see differences in most of the anterior segment presentations. This can be attributed to the geographical change in location of the study. The prevalence of adnexal manifestations in our study was 10.83%. Most common adnexal manifestation was found to be conjunctival microvasculopathy (4.2%) seen in 5 patients, followed by blepharitis (2.5%) seen in 3 patients. The pathogenesis of blepharitis in immunodeficient individuals may either involve a reduced ability to control normal flora or more complex changes in cutaneous glands of the eyelids that occur with immunosuppression. On comparing our study with Aacharya et al[3] and Ushalatha et al,[8] we found a similar prevalence of blepharitis and conjunctival microvasculopathy. Herpes zoster ophthalmicus (HZO) (1.7%) was seen in 2 patients, Ocular surface squamous neoplasia (OSSN) in 2 patients (1.7%) and Molluscum contagiosum in one patient (0.8%). It shows that Squamous cell carcinoma is more prevalent than Kaposi's sarcoma in south Asian countries due to the low prevalence of human herpes virus type 8. Five patients (4.2%) had Neuro ophthalmological lesions, most common being optic atrophy(1.7%), followed by cranial nerve palsy (0.8%), papilloedema (0.8%) and optic neuritis (0.8%). The prevalence of neuro-ophthalmological lesions in our study was around 4.2%. Our study findings are comparable to the studies by Narwade et al,[6] Sudharshan et al,[7]Aacharya et al[3] and Ushalatha et al.[8]

CONCLUSION

Though prevalence of ocular manifestations in our study was higher, the prevalence of visual impairment was very low. This signifies that the use of Highly active anti-retroviral therapy (HAART) has led to reduction in prevalence of opportunistic infections like CMV retinitis which is the main cause of visual impairment in HIV positive patients. Most of the ocular manifestations were asymptomatic, hence, screening for ocular symptoms is not a reliable method for identifying those with ocular manifestations. Ocular manifestations were observed even in early stages of HIV infection. Hence, our study highlights the need for a routine ophthalmological screening of all HIV seropositive patients regardless of their immune status.

REFERENCES

1. Annual Report NACO 2016-17.http://naco.gov.in/documents/annual-reports.
2. Sahu DK, Namperumalsamy P, Walimbe P, Rajalakshmi C. Ocular manifestations of HIV infection in south Indian patients. Ind J Ophthalmol 1999; 47:79-85.
3. Acharya PK, Venugopal KC, Karimsab DP, Balasubramanya S. Ocular Manifestations in Patients with HIV Infection/AIDS who were Referred from the ART Centre, Hassan, Karnataka, India. J Clin Diagn Res. 2012; 6(10):1756-60.
4. Sudharshan S, Biswas J. Symposium on Anterior segment manifestations of Human immunodeficiency virus/acquired immune deficiency syndrome. Indian Journal of Ophthalmology 2008; 56: 363-75.
5. Pathai S, Deshpande A, Gilbert C, Lawn SD. Prevalence of HIV associated ophthalmic disease among patients enrolling for anti retroviral treatment in India. BMC Infectious Diseases. 2009; 9: 158.
6. Narwade V, Joshi BS, Sindal DK, Karambelkar VH. A clinical study of ocular manifestations in HIV infection and their correlation with selected variables. Medpulse-Int Med J 2017; 4(2):177-181.
7. Sudharshan S, Kaleemunnisha S, Banu AA, et al. Ocular lesions in 1,000 consecutive HIV-positive patients in India: a long-term study. J Ophthalmic Inflamm Infect. 2013; 3(1):2.
8. Ushalatha B, Bhavani MV. Ocular Manifestations In HIV/AIDS. IOSR Journal of Dental and Medical Sciences (IOSR-JDMS) 2016; 15(4):27-35.

Source of Support: None Declared
Conflict of Interest: None Declared