Original Research Article

# Role of surgical management of clavicle fracture

Avinash Kumar[1], Kunal Prashad[2*]

[1]Senior Resident, [2]Junior Resident, Department of Orthopedics, M.G.M.Medical College and L.S.K. Hospital, Kishanganj, Bihar. INDIA.
**Email:** kajal6160@gmail.com

## Abstract

**Background:** Many methods of treatment for fractures of the clavicle had been described even though a sling consistently gave good functional results. **Methods:** Patients aged between 25-75 having clavicular fracture of middle one third who were admitted in M.G.M Medical College and L.S.K Hospital, Kishanganj at the period of January 2018 to August 2019 was included in the study. Estimated sample size was 60 divided into two groups consisting 30 patients each. **Results:** The average age in the plating group was 32.30 ± 7.28 (range 16–60)years and in the elastic nailing group it was 31.16 ± 6.33 (range 16-60) years. Both groups showed no statistical difference in term of age ($p = 0.92$). Majority of the patients, fracture shows in left side among two groups in our study subject. i.e. 60% in group A and 70% in group B The chi-square value was 0.659 and p value was 0.41 statistically not significant. In our study we evaluated 40 cases of midshaft clavicular fractures treated by ORIF with plating (30 cases) and titanium elastic nailing (30 cases). Functional outcome in terms of early mobilization, clinical union and radiological union found to Statistically significant with p-value was <0.001. (All values less than <0.05). Hence patients treated with titanium elastic nailing had good functional outcome and good anatomical reduction. **Conclusion:** When compared to plating nailing has excellent functional outcome and minimal complications.

**Key Word:** clavicle fracture.

***Address for Correspondence:**
Dr Kunal Prashad, Junior Resident, Department of Orthopedics, M G M Medical College and L.S.K. Hospital, Kishanganj, Bihar. INDIA
**Email:** kajal6160@gmail.com
Received Date: 06/11/2019 Revised Date: 21/12/2019 Accepted Date: 30/01/2020
DOI: https://doi.org/10.26611/10201331

| Access this article online | |
|---|---|
| Quick Response Code: | Website: www.medpulse.in |
| | Accessed Date: 01 March 2020 |

## INTRODUCTION

The incidence of clavicle fractures has increased in recent years and the operative treatment of these fractures has increased disproportionately.[1,2] Clavicle fractures are most commonly classified according to the Allman classification and/or the Robinson classification. The location and type of fracture is important in the decision-making as it influences management strategies. Described conservative treatment options for the clavicle fracture consist of pain reduction by temporary immobilization using a sling or collar and cuff in combination with analgesics and/or kinesio tape. Operative treatment comprises open reduction and internal fixation (ORIF) using plates and screws or intramedullary fixation (IMF), of which the titanium elastic nail (TEN) is the most commonly used and described option.[3] Classical operative treatment indications are open fractures, compromised skin, neurovascular complications or an additional fracture of the scapular neck (floating shoulder).[12,13] Others have described relative indications for operative management, which are displaced midshaft clavicle fractures, a shortening of ⩾ 2 cm, age, activity level and dominant side.[4] The majority (69–82%) of fractures occur in the midshaft of the clavicle, followed by 12–26% in the lateral part and 2–6% in the medial part[5]. This can be anatomically explained by the fact that the medial and lateral parts of the clavicle are firmly secured by strong ligaments and muscles, whereas the middle part of the clavicle lacks any strong attachments and thus is more vulnerable to trauma. The muscle attachments often cause a dislocation of the major fragments in clavicle fractures and a shortening of the clavicle, particularly in midshaft

How to site this article: Avinash Kumar, Kunal Prashad. Role of surgical management of clavicle fracture. *MedPulse International Journal of Orthopedics.* March 2020; 13(3): 30-34. https://www.medpulse.in/Orthopedies/

fractures[6]. Traditionally, clavicle fractures have been treated almost exclusively non-operatively, regardless of the type of fracture. Studies in the 1960s described good functional results for non-operatively treated midshaft clavicle fractures and a lower nonunion rate compared to fractures treated with primary open reduction[7]. In contrast, several more recent studies have reported opposite results with newer methods of fracture fixation[8], which may have contributed to the 705% increase in operative treatment of clavicle fractures in Sweden between 2001 and 2012[9]. Optimal treatment of clavicle fractures however remains a debated subject. The most commonly used operative method today is open reduction and internal plate fixation; a smaller number of fractures are treated with intramedullary nails, pins or wires[8].

## METHODOLOGY

Patients aged between 16-60 having clavicular fracture of middle one third who were admitted in M.G.M Medical College and L.S.K Hospital, Kishanganj was included in the study. Estimated sample size was 60 divided into two groups consisting 30 patients each.

**Group A:** Locking Compression Plate Fixation-30

**Group B:** Titanium Elastic Iintramedullary Nail Fixation-30

**Method used:** Locking Compression Plate Fixation(LCP). Titanium Elastic Intramedullary Nail Fixation(TENS).

**Preoperative assessment**: All the cases were studied in the following manner: History by verbal communication. Clinical examination. Base line investigations. Routine radiological examination. Written and informed consent was taken for surgical procedure.

**Exclusion Criteria:** Age <16years. Fractures with marked comminution. Fractures older than 4 weeks. Pathological fractures. Open fractures. Congenital anamoly or bone disease. High anaesthetic risk

**Methodology and surgical procedure:** We conducted a prospective comparative study to compare outcomes and complications of closed displaced midshaft clavicular fractures treated with precontoured dynamic compression plates or with single titanium elastic intramedullary nails. Between January 2018 to August 2019, a total of 60 patients with closed displaced midshaft clavicular fractures were admitted in our hospital. In this study, these patients were randomized according to inclusion and exclusion criteria into two equal groups of 30 patients, to be treated surgically with either a 3.5-mm precontoured dynamic compression plate (LCP group) or with a single Titanium Elastic Intramedullary Nail Fixation (TENS group).

Patients were randomized into two groups by the concealed envelope technique. The Robinson [10] classification system is the most valuable in terms of choosing therapy, as well as being of prognostic value for midshaft clavicular fractures.

**Plate and nail size used**

- Locking Plate (Anatomical Plate) Used
- 3.5 mm Reconstruction Plate Used
- 2.5 mm TENS Nail Used
- 2 mm TENS Used

**Need for implant exit:** Among 30 cases operated with LCP 2 cases got infected, clinically infection found to be superficial. Clinical and radiological evidence of union was noted. Implant exit done after 20 weeks, infection settled down after removal of implant. Among 30 cases operated with TENS exit done for 10 cases after confirming clinical and radiological evidence of union. Implant exit done as outpatient procedure under local anaesthesia.

**Surgical methods and post operative protocol:** All patients were received in emergency OPD, after initial stabilization patient were clinically evaluated for life threatening injuries. After ruling out life threatening injuries patient initially immobilized with strapping cuff andcollar and clavicle brace and then patient shifted to our ward. Planning of surgical management based on X-Ray findings, patient demand, displacement, type of fracture and associated injuries. All the cases operated within 3rd - 5th day of admission.

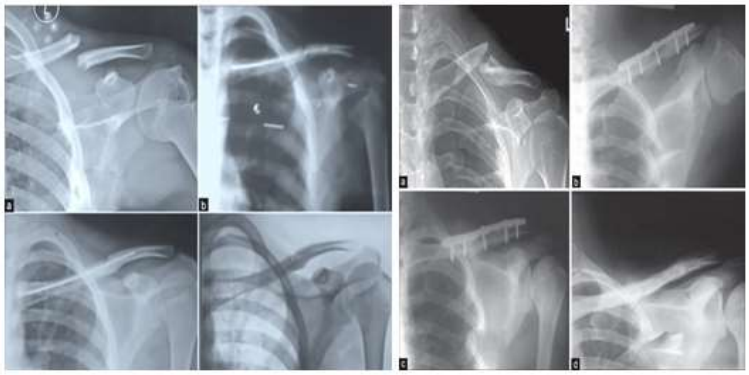

Nail Fixation Plate Fixation

# RESULTS

**Table 1:** Mean and SD value of Age among Two groups

| Age Distribution | Group A (LCP) (n=30) | | Group B (TENS) (n=30) | |
|---|---|---|---|---|
| | Mean | SD | Mean | SD |
| | 28.100 | ±5.10 | 27.966 | ±5.14 |
| P Value- 0.92 (NS) | | | | |

The average age in the plating group was 28.100 ± 5.10 (range 16–60) years and in the elastic nailing group it was 27.966 ± 5.14 (range 16–60) years. Both groups showed no statistical difference in term of age ($p = 0.92$).

**Table 2:** Gender Distribution among two groups

| Sex Distribution | Group A (LCP) (n=30) | | Group B (TENS) (n=30) | |
|---|---|---|---|---|
| | No | % | No | % |
| Male | 27 | 90.0 | 25 | 83.3 |
| Female | 03 | 10.0 | 05 | 16.7 |
| **Total** | **30** | **100** | **30** | **100** |
| $\chi^2 = 0.577$, df = 1, $\chi^2/df = 0.58$ , $P(\chi^2 > 0.577) = 0.44$ (NS) | | | | |

Majority of the patients among two groups in our study subject were male. The male and female ratio among Group A (LCP) was 9:1 and Group B (TENS) 5:1 respectively. The chi-square value was 0.577 and p value was 0.44 i.e. not significant.

**Table 3:** Side of injury among two groups

| Side of Injury | Group A (LCP) (n=30) | | Group B (TENS) (n=30) | |
|---|---|---|---|---|
| | No | % | No | % |
| Right | 12 | 40.0 | 09 | 30.0 |
| Left | 18 | 60.0 | 21 | 70.0 |
| **Total** | **30** | **100** | **30** | **100** |
| $\chi^2 = 0.659$, df = 1, $\chi^2/df = 0.66$ , $P(\chi^2 > 0.659) = 0.41$ (NS) | | | | |

Majority of the patients, fracture shows in left side among two groups in our study subject. i.e. 60% in group A and 70% in group B The chi-square value was 0.659 and p value was 0.41 statistically not significant.

**Table 4:** Mode of injury among two groups

| Mode of injury | Group A (LCP) (n=30) | | Group B (TENS) (n=30) | |
|---|---|---|---|---|
| | No | % | No | % |
| RTA | 20 | 66.6 | 18 | 60 |
| Fall | 08 | 26.7 | 09 | 30 |
| Assault | 02 | 6.7 | 03 | 10.0 |
| **Total** | **30** | **100** | **30** | **100** |
| $\chi^2 = 0.364$, df = 2, $\chi^2/df = 0.18$ , $P(\chi^2 > 0.364) = 0.83$ (NS) | | | | |

The common mode of injury was RTA involving total 60(A+B group) patients among them 20(60.6%) belonged to LCP group and 18(60.0%) belonged to TENS group. And It was statistically not significant (p value- 0.83).

**Table: 5.** Intra-operative outcome comparisons among two groups

| . Intra-operative outcome | Group A (LCP) (n=30) | | Group B (TENS) (n=30) | | p Value |
|---|---|---|---|---|---|
| | Mean | SD | Mean | SD | |
| Operative Time(Min) | 71.266 | ±10.08 | 50.866z | ±4.15 | <0.001(S) |
| Per-operative Blood Loss(ml) | 156.333 | ±16.29 | 55.166 | ±9.86 | <0.001(S) |

**Table 6:** Reduction during Surgery among two groups

| Reduction during Surgery | Group A (LCP) (n=30) | | Group B (TENS) (n=30) | |
|---|---|---|---|---|
| | No | % | No | % |
| ORIF | 30 | 100 | 12 | 40.0 |
| CRIF | 00 | 00 | 18 | 60.0 |
| **Total** | **30** | **100** | **30** | **100** |
| $\chi^2 = 25.714$, df = 1, $\chi^2/df = 25.71$ , $P(\chi^2 > 25.714) = <0.001$( S) | | | | |

**Table 7:** Functional Outcomes among two groups

| Functional Outcomes | Group A (LCP) (n=30) | | Group B (TENS) (n=30) | | p Value |
|---|---|---|---|---|---|
| | Mean | SD | Mean | SD | |
| Mobilizat ion Started (days) | 16.866 | ±1.54 | 8.700 | ±1.34 | <0.001 |
| Clinical union (weeks) | 8.733 | ±0.90 | 7.400 | ±0.49 | <0.001 |
| Radio. Union (weeks) | 12.900 | ±1.12 | 8.266 | ±0.73 | <0.001 |

**Table 8:** Post operative complications among two groups

| complications | Group A (LCP) (n=30) | | Group B (TENS) (n=30) | |
|---|---|---|---|---|
| | No | % | No | % |
| Delayed union | 24 | 80 | 21 | 70 |
| Delayed unionand Shoulder stiffness | 02 | 6.7 | 02 | 6.7 |
| Infection | 02 | 6.7 | 00 | 00 |
| Delayed union, Infection and stiffness | 02 | 6.7 | 00 | 00 |
| Nail migration | 00 | 00 | 05 | 16.6 |
| Skin irritation | 00 | 00 | 02 | 6.7 |
| **Total** | **30** | **100** | **30** | **100** |
| $\chi^2 = 11.200$, df = 5, $\chi^2/df = 2.24$ , $P(\chi^2 > 11.200) = 0.04$ (S) | | | | |

## DISCUSSION

Clavicle fractures are one of the most common fractures of young active individuals. Most of the clavicle fractures managed by conservative method previously but after understanding the fracture biomechanics of clavicle surgical management found to have good functional outcome and early mobilization of patients. Fracture patterns like displaced, comminuted, shortening>2 cm all have impact on union and functional outcome. In our study 30 patients treated with ORIF with plating, another 30 patients treated with CRIF/ORIF with elastic nailing. Though each procedure having advantages and disadvantages the functional outcome of surgical methods. We found TENS methods to be better when compared to clavicular locking plate methods. Elastic nailing not indicated for comminuted fractures and fracture nonunion. The advantage of intra medullary fixation and not disturbing the fracture hematoma are additive features of closed nailing. In our study we evaluated 60 cases of midshaft clavicular fractures treated by ORIF with plating (30 cases) and titanium elastic nailing (30 cases). Functional outcome in terms of early mobilization, clinical union and radiological union found to Statistically significant with p-value was <0.001. (All values less than <0.05). Hence patients treated with titanium elastic nailing had good functional outcome and good anatomical reduction.

### Analysis of various studies

Previous literatures and studies compared the functional outcome of conservative methods and plating, conservative methods and nailing. But only small numbers of studies were comparing plating versus nailing. Our study compared the functional outcome of plating versus nailing.

| Results | Zlodowski *etal.*(2005)[11] 2144 cases | | Thiyagara- jan *et al.* (2005)[12] | | Zlodowski *et al.* (2007)[13] | | Smekal *et al.*(2009)[14] 60cases | | Chen QY *et al.* (2011) 60cases | | S. Balachandar *et al.* (2017)[15] 30 cases | | Our study (2019) 60 cases. | |
|---|---|---|---|---|---|---|---|---|---|---|---|---|---|---|
| Nonunion | 2.5% | 1.6% | - | 24% | 2 | 3 | 3 | - | 1 | - | nil | nil | nil | nil |
| Malunion | nil | nil | nil | nil | nil | nil | nil | nil | nil | nil | nil | nil | nil | nil |
| Infection | 2.4% | nil | nil | nil | - | - | nil | nil | nil | nil | nil | nil | 6.7% | nil |
| Nail migration | - | - | | - | - | - | - | - | nil | 5 | nil | 2 | nil | 5 |

Our study shows good functional outcome for Elastic Nailing when compared to Plating with significant value of ($P < 0.05$).

## CONCLUSION

Nonsurgical methods are nowadays used in elderly patients with less physiological demand. But increasing evidence of good functional outcome of surgical methods favors fixation for young individuals and elderly patients with physiological demand. Good anatomical reduction for comminuted fractures and no need for implant exit are merits of plating. But surgical scar and chances of infection are more in plating. Intramedullary fixation, minimally invasive and early mobilization are the merits of elastic nailing. But need for implant exit and inadequate fixation for comminuted fractures are demerits of nailing. In conclusion titanium elastic nail size of 2 – 2.5mm diameter is recommended for displaced midshaft clavicle fractures. When compared to plating nailing has excellent functional outcome and minimal complications.

## REFERENCES


1. Huttunen TT, Launonen AP, Berg HE, *et al...* Trends in the incidence of clavicle fractures and surgical repair in Sweden: 2001-2012. J Bone Joint Surg [Am] 2016;98-A:1837-1842.
2. chairer WW, Nwachukwu BU, Warren RF, Dines DM, Gulotta LV. Operative fixation for clavicle fractures-socioeconomic differences persist despite overall population increases in utilization. J Orthop Trauma 2017;31:e167-e172.
3. Kadakia AP, Rambani R, Qamar F, *et al...* Titanium elastic stable intramedullary nailing of displaced midshaft clavicle fractures: A review of 38 cases. Int J Shoulder Surg 2012;6:82-85.
4. AO Foundation. AO/OTA fracture and dislocation classification: Clavicle diagnosis. (date last accessed 18 December 2017).
5. Postacchini F, Gumina S, De Santis P, Albo F. Epidemiology of clavicle fractures. J Shoulder Elbow Surg. 2002;11(5):452–456. doi: 10.1067/mse.2002.126613.
6. Smekal V, Oberladstaetter J, Struve P, Krappinger D. Shaft fractures of the clavicle: current concepts. Arch Orthop Trauma Surg. 2009;129(6):807–815. doi: 10.1007/s00402-008-0775-7.
7. Neer CS., 2nd Nonunion of the clavicle. J Am Med Assoc. 1960;172:1006–1011. doi: 10.1001/jama.1960.03020100014003.
8. Virtanen KJ, Remes V, Pajarinen J, Savolainen V, Bjorkenheim JM, Paavola M. Sling compared with plate osteosynthesis for treatment of displaced midshaft clavicular fractures: a randomized clinical trial. J Bone Joint Surg Am. 2012;94(17):1546–1553. doi: 10.2106/JBJS.J.01999.
9. Huttunen TT, Launonen AP, Berg HE, Lepola V, Fellander-Tsai L, Mattila VM. Trends in the Incidence of Clavicle Fractures and Surgical Repair in Sweden: 2001–2012. J Bone Joint Surg Am. 2016;98(21):1837–1842. doi: 10.2106/JBJS.15.01284.
10. Robinson CM. Fractures of the clavicle in the adult. Epidemiology and classification. J Bone Joint Surg Br. 1998;80(3):476–48.
11. postoperative protocol all have convincingly improved the good functional outcome Zlodowski *et al...* (2005)
12. intramedullary fixation, midshaft clavicle fractures. Introduction Zlodowski *et al...* (2007)
13. Smekal V(1), Irenberger A, Struve P, Wambacher M, Krappinger D, Kralinger FS. Comment in J Bone Joint Surg Am. 2009 Nov;91(11):2746.
14. Chen Q-Y, Kou DQ, Cheng XJ,.Clavicle fractures are common fractures and the optimal treatment strategy .... a) Example of plate fixation of a clavicle fracture (patient treated in .... J Orthop Traumatol 2011;12:185-192.
15. Balachandar. S" Outcome of plate and intramedullary fixation of midshaft clavicle fractures: a search for optimal surgical management" International Journal of Orthopaedics Sciences 2017; 3(3): 1050-1061 ;2017


Source of Support: None Declared
Conflict of Interest: None Declared