

# Study of management of 10 complicated cases of distal tibial fractures in tribal population

Nandkishor Goyal<sup>1</sup>, Prashant More<sup>2</sup>, Varun Nishandar<sup>3\*</sup>

<sup>1</sup>Associate Professor, <sup>2</sup>Assistant Professor, <sup>3</sup>Junior Resident, ACPM Medical College Dhule, Maharashtra, INDIA.

Email: [dr.varoon.nishandar@gmail.com](mailto:dr.varoon.nishandar@gmail.com)

## Abstract

Distal tibia fractures are complex injuries with a high complication rate. In this retrospective, study, we attempted to detail complications and outcomes of this type of injury in order to determine predictive factors of poor results. Between 2015 and 2017, 10 patients were admitted for distal tibia fractures. Internal fixation, external fixation, limited internal fixation (K-wires or screws), intramedullary nailing and conservative treatment were the different mode of treatment. The complications occurred in 3 patients. Predictive factors of poor results were fracture severity, complications, malunion severe skin and soft tissue injury. We believe that external fixation must be reserved for trauma with severe skin and soft tissue injury, as a temporary solution in a one/two-staged protocol. For other cases, we recommend ORIF with early mobilization.

**Key Word:** Fracture lower third tibia/fibula, plating, healing, tribal population.

## \*Address for Correspondence:

Dr. Varun Nishandar, Room no. 501, ACPM Boys Hostel, ACPM Medical College Campus, Opp Jawahar Soot Girni, Sakri Road, Dhule-424001, Maharashtra, INDIA.

Email: [dr.varoon.nishandar@gmail.com](mailto:dr.varoon.nishandar@gmail.com)

Received Date: 05/09/2018 Revised Date: 21/10/2018 Accepted Date: 19/11/2018

DOI: <https://doi.org/10.26611/1020835>

## Access this article online

Quick Response Code:



Website:

[www.medpulse.in](http://www.medpulse.in)

Accessed Date:  
22 December 2018

## INTRODUCTION

Management of distal tibia fractures, with or without articular involvement, is a therapeutic challenge<sup>1,2</sup>. The goal of orthopaedic surgeons is to restore the tibial anatomy, to fix the epi-metaphyseal block with the diaphysis and to avoid complications. Many osteosynthesis techniques can be used for these fractures such as; traditional open reduction and internal fixation (ORIF), external fixation with or without limited internal fixation, intramedullary nailing or, more recently, minimally invasive plate osteosynthesis (MIPO)<sup>5,9</sup>. All of these techniques have advantages and disadvantages and there is no consensus concerning the management of these fractures<sup>2,10</sup>. Despite progress of surgical

procedures, outcomes are not always excellent and complications affect 20–50% of patients<sup>2,11,12</sup>. The purpose of this paper was to study the functional and radiographic outcomes after distal tibia fractures, to evaluate complications and to determine predictive factors of poor results.

## MATERIALS AND METHODS

### Description of patients

This retrospective study concerned 10 patients with all distal tibia fractures from 2015 to 2017. All Patient were from ACPM Medical college, orthopedic department. The study group included 3 women and 7 men with an average age of 44 years (range:25–66 years). There was one bilateral case. Thus we obtained a group of 10 consecutive fractures patients. High-energy injury (i.e. road traffic accident) occurred in 7 cases and 3 had fall from height. We classified the distal tibia fractures according to the AO/OTA classification<sup>2</sup> as type (metaphyseal) with distinction of type-A fractures (extra-articular), type-B (partial articular) and type-C (total articular)<sup>1</sup> Open fractures were classified according to the Gustilo classification for open fractures and involved 1 patients (type IIIA). There were No preoperative nerve injuries or vascular injury requiring specialized management. No patients had multiple injuries.

### Surgical procedures

Type of osteosynthesis and surgical approach were determined by the surgeon according to the fracture type, fragments localisation and skin injury. Open fractures were treated within 24 hours of injury as were the fractures without skin damage. Open reduction and internal fixation. DCP/ locking plates or AO plates were used in this study. The surgical approach was determined by the local state of the skin (wound, blister, etc.). Generally approaches were anteromedial. Postoperatively all patients were mobilized on a non weight-bearing cast for an average period of 70 days. Full weight-bearing was allowed after an average period of 90 days [when callus was seen]. Ipsilateral fibular fracture occurred in 6 cases (60%) and were treated by open reduction and internal fixation in all cases using plate or rush nail. Fibular Osteosynthesis was done mostly to restore the length of the tibia and to control the rotation effect in the ORIF group or the internal fixation group.

At final follow-up, clinical examination was made in our hospital where the procedure was performed and all subjects gave their informed consent prior to their inclusion in the study. Range of motion (ROM) seen; it was 50 -60degrees. Result were fair as compared with literature. Radiological records included initial, postoperative and final follow-up X-rays.

### RESULTS

The average follow-up was 6 months. However, regarding the injury data, we noted that external fixation was used mostly for open fractures in case of polytrauma (*one case*).

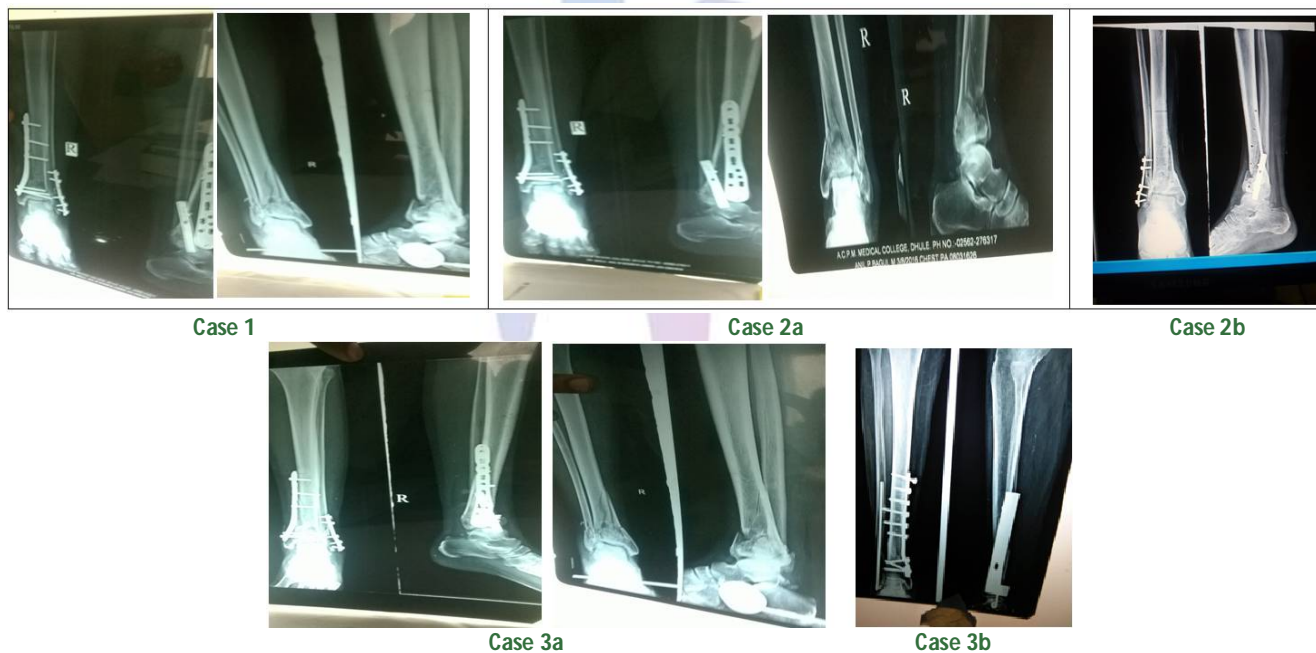
### Complications

Surgical complications i.e. surgical site infection occurred in 2 patients which were successfully treated with intravenous antibiotics.

### Clinical outcomes

Results were excellent in 3 cases, good in 5, fair in 2 cases. Intra-articular step-off did not influence the functional score.

### METHODOLOGY



**Case 1:** Pre & Post –op x-ray; **Case 2a:** Pre & post –op x-ray- after healing of fracture; **Case 2b:** Plate removed due to infection; **Case 3a:** Pre & post –op x-ray; **Case 3b:** After 6 month follow-up

### DISCUSSION

This retrospective study of 10 patients confirms the difficulty of distal tibia fracture management and the high complication rate. Postoperative complications concerned 30% of patients and were mostly infectious or cutaneous problems. This rate is comparable to other series with rates ranging from 20% to 30%<sup>2, 9,11,12</sup>. As others have pointed out, we found a correlation between complication rate and initial fracture severity<sup>6,12</sup>. In the same way, high

fracture severity, complications or malunion were associated with poor clinical results. The best clinical results were observed for the limited internal fixation group. Open reduction and internal fixation with a plate permitted a correct and stable fracture reduction with good clinical results without any increase of cutaneous or infection complication rate, contrary to other authors<sup>11,12,16</sup>. For the external fixation group, no two-staged protocol was undertaken in this study and external

fixation was always a definitive device. Similar to many other authors, we found that definitive external fixation provided fair result. There was no stiffness or pain. Our ipsilateral fibular fracture rate was small [60%] in comparison to rates near 80% found in the literature<sup>17,18</sup>. This difference may be explained by the injury mechanisms in our study. Indeed, we had fewer high energy injuries than Lee et al. (73% in our study versus 91% for Lee et al.)<sup>17</sup>. We recommend a fibular osteosynthesis with a plate as often as possible in order to restore the length of the tibia, to control rotation forces. Distal tibia fractures are complex cases and need appropriate treatment to limit the incidence of complications. For acute fractures without skin injury, we prefer a stable and rigid internal fixation in a one-staged procedure. Limited internal fixation can be used for fractures without comminution and easily reducible by traction or external manipulation. However, with this technique, a non weight-bearing cast is recommended. ORIF with conventional or locking plates should be used for comminuted cases in order to reduce the articular surface perfectly. Surgical approaches must preserve the soft tissue and can be anteromedial or anterolateral according to surgeon preference and fracture localization. One advantage of the locking plate is to permit faster full weight-bearing and stronger fracture stabilization as an internal fixator. For fractures with skin injury, consists of an approximate reduction and application of an external fixator spanning the ankle joint. There was only one patient with compound fracture in whom External fixation was used as a definitive device with good result.

## CONCLUSION

Distal tibia fractures remain a therapeutic challenge for orthopedic surgeons. According to the literature, these fractures are often associated with a high complication rate<sup>2,9,11,12</sup>. Based on our study, We believe that external fixation must be reserved for trauma with severe skin and soft tissue injury. For other cases, we recommend ORIF with early obilization.

## REFERENCES

1. Sirkin M, Sanders R. The treatment of pilon fractures. *Orthop Clin North Am.* 2001;32:91–102. doi: 10.1016/S0030-5898(05)70196-6.
2. Marsh JL, Saltzman CL. Ankle fractures. In: Bucholz RW, Heckman JD, Court-Brown CM, editors. *Rockwood & Green's fractures in adults.* 6. Philadelphia: Lippincott Williams & Wilkins; 2006. pp. 2147–2247.
3. Blauth M, Bastian L, Krettek C, Knop C, Evans S. Surgical options for the treatment of severe tibial pilon fractures: a study of three techniques. *J Orthop Trauma.* 2001;15:153–160. doi: 10.1097/00005131-200103000-00002.
4. Copin G, Nérot C. Recent fractures of the tibial pilon in adult (*Symposium du 66ème Congrès de la SOFCOT*) *Rev Chir Orthop.* 1992;78(Suppl-1):3–83.
5. Pugh KJ, Wolinsky PR, McAndrew MP, Johnson KD. Tibial pilon fractures: a comparison of treatment methods. *J Trauma.* 1999;47:937–941. doi: 10.1097/00005373-199911000-00022.
6. Zelle BA, Bhandari M, Espiritu M, Koval KJ, Zlowodzki M. Treatment of distal tibia fractures without articular involvement: a systematic review of 1125 fractures. *J Orthop Trauma.* 2006;20:76–79. doi: 10.1097/01.bot.0000202997.45274.a1.
7. Pollak AN, McCarthy ML, Bess RS, Agel J, Swiontkowski MF. Outcomes after treatment of high-energy tibial plafond fractures. *J Bone Joint Surg Am.* 2003;85-A:1893–1900.
8. McFerran MA, Smith SW, Boulas HJ, Schwartz HS. Complications encountered in the treatment of pilon fractures. *J Orthop Trauma.* 1992;6:195–200. doi: 10.1097/00005131-199206000-00011.
9. Teeny SM, Wiss DA. Open reduction and internal fixation of tibial plafond fractures. Variables contributing to poor results and complications. *Clin Orthop Relat Res.* 1993;292:108–117.
10. Gustilo RB, Mendoza RM, Williams DN. Problems in the management of type III (severe) open fractures: a new classification of type III open fractures. *J Trauma.* 1984;24:742–746. doi: 10.1097/00005373-198408000-00009.
11. Tarkin IS, Clare MP, Marcantonio A, Pape HC. An update on the management of high-energy pilon fractures. *Injury.* 2008;39:142–154. doi: 10.1016/j.injury.2007.07.024.
12. Lee YS, Chen SW, Chen SH, Chen WC, Lau MJ, Hsu TL (2008) Stabilisation of the fractured fibula plays an important role in the treatment of pilon fractures: a retrospective comparison of fibular fixation methods. *Int Orthop* 33(3):695–699
13. Topliss CJ, Jackson M, Atkins RM. Anatomy of pilon fractures of the distal tibia. *J Bone Joint Surg Br.* 2005;87:692–697. doi: 10.1302/0301-620X.87B5.15982.
14. 1920. Ozsoy MH, Tuccar E, Demiryurek D, Bayramoglu A, Hayran M, Cavusoglu AT, Dincel VE, et al. Minimally invasive plating of the distal tibia: do we really sacrifice saphenous vein and nerve? A cadaver study. *J Orthop Trauma.* 2009;23:132–138.
15. Dickson KF, Montgomery S, Field J. High energy plafond fractures treated by a spanning external fixator initially and followed by a second stage open reduction internal fixation of the articular surface—preliminary report. *Injury.* 2001;32(Suppl 4):92–98. doi: 10.1016/S0020-1383(01)00163-2.

Source of Support: None Declared  
Conflict of Interest: None Declared