

Efficacy and safety of oral fluconazole vs topical antifungal imidazoles in tinea corporis: A comparative therapeutic trial

Mohamed Salim Valiyakathoy¹, Soopy Kayanaduth^{2*}, Roopashree Gopinath³

¹Assistant Professor, Department of Pharmacology, Government Medical College, Kozhikode, Kerala, INDIA.

²Associate Professor, Department of General Medicine, Government Medical College, Kozhikode, Kerala, INDIA.

³Kaplan University, Davenport, Iowa, USA.

Email: drsoopy@gmail.com

Abstract

Background: Dermatophytes are the most common causes of superficial fungal infections worldwide. All dermatophytosis of glabrous skin except the palms, soles and groin are categorized under tinea corporis. Dermatophytic infections may be treated with both topical and systemic therapies. The present study aims to assess the efficacy and safety of oral fluconazole in comparison to topical antifungal miconazole nitrate and ketoconazole against tinea corporis. **Methodology:** This study is an open labelled comparative trial. About 60 patients (n = 60) with dermatophytosis attending outpatient clinic of dermatology department of Government Medical College, Kozhikode, Kerala, India, were selected randomly. The diagnosis and prognosis was done by clinical and microscopic examination by mounting skin scrapings in 10% KOH solution. The comparison of efficacy was done by chi-square test. The cure rate in each group was expressed as percentage. *P* value of <0.05 was considered significant and <0.01 as highly significant. **Results:** The cure rate in tinea corporis with oral fluconazole therapy at the dose of 150 mg weekly for 3 weeks was 100 %. The cure rate observed with miconazole and ketoconazole were 60% and 53% respectively. Fluconazole treatment does not resulted in serious adverse effects and safer for short term therapy of tinea corporis. **Conclusion:** Oral fluconazole is more effective than topical antifungal agents like miconazole nitrate and ketoconazole for the treatment of tinea corporis.

Key Word: dermatophytosis, tinea corporis, fluconazole, miconazole, ketoconazole.

Address for Correspondence

Dr. Soopy Kayanaduth, Associate Professor, Department of General Medicine, Government Medical College, Kozhikode, Kerala, Pin: 673008 INDIA.

Email: drsoopy@gmail.com

Received Date: 10/03/2018 Revised Date: 14/04/2018 Accepted Date: 28/04/2018

DOI: <https://doi.org/10.26611/1010611>

Access this article online

Quick Response Code:



Website:

www.medpulse.in

Accessed Date:
30 April 2018

INTRODUCTION

Dermatophytosis refers to superficial fungal infection of the skin, hair and nail caused by keratinophilic fungi called dermatophytes. Dermatophytes are the most common causes of superficial fungal infections worldwide. They are classified into three groups based on

their genera: a). *Trichophyton* - causes infections on skin, hair, and nails. b). *Epidermophyton* - causes infections on skin and nails. c). *Microsporum* - causes infections on skin and hair. Depending on whether a species be located predominantly in the soil, on animals or on humans, it is said to be geophilic, zoophilic or anthropophilic respectively. Furthermore, based upon the affected site, these have been classified clinically into tinea faciei (face), tinea capitis (head), tinea barbae (beard), tinea manus (hand), tinea corporis (body), tinea cruris (groin), tinea pedis (foot), and tinea unguium (nail)^{1,2}. Typical dermatophytosis have an annular appearance that is commonly referred to as ringworm or tinea¹. Tinea corporis denotes to all dermatophytosis of glabrous skin except the palms, soles and groin³. All species of dermatophytes belonging to the genera *Trichophyton*, *Microsporum* or *Epidermophyton* can cause tinea corporis. The four most common dermatophytes that

cause tinea corporis are *Trichophyton rubrum*, *Trichophyton mentagrophytes*, *Microsporum canis* and *Trichophyton tonsurans*. In India, *T. rubrum* accounts for the majority of cases of tinea corporis^{4,7}. The high environmental temperature and relative humidity of tropical and subtropical countries like India, particularly favors in precipitating tinea corporis. The higher incidence of tinea corporis is also associated with increased urbanization including the use of occlusive footwear and clothing. Tinea corporis may be transmitted by direct contact with other infected individuals or by infected animals⁸. Dermatophytic infections may be treated with both topical and systemic therapies. Topical therapy is generally effective for uncomplicated tinea corporis of small areas⁹. Several topical antifungals of different groups such as azole derivatives, allylamines, benzylamines, morpholine, etc. are effective in localized dermatophytoses. Most commonly used topical antifungal therapy are based on the use of imidazoles, such as clotrimazole, miconazole, and ketoconazole¹⁰. Whereas, systemic drugs, like terbinafine and itraconazole, are widely used for the treatment of severe and chronic dermatophytosis¹¹. Azole group of antifungal drugs include both imidazoles and triazoles. Miconazole and ketoconazole, belongs to the chemical class of imidazoles, are known for its proven antifungal activity. Miconazole has been used to treat superficial fungal infections since the early 1970s^{12,14}. Ketoconazole is also an anti-fungal agent that has been topically used to stop the growth of dermatophytes¹⁵. Fluconazole, is a bis-triazole broad spectrum antifungal agent available as oral tablet, oral suspension and intravenous formulation. Like other imidazoles, fluconazole inhibits sterol incorporation into fungal cell walls and exerts the antifungal effects¹⁶. Although, fluconazole, miconazole and ketoconazole are used for the treatment of tinea corporis, there is paucity in information of comparative study regarding the clinical

efficacy of oral fluconazole and topical imidazoles. Thus the present study aims to assess the efficacy and safety of oral fluconazole in comparison to topical antifungal miconazole nitrate and ketoconazole against tinea corporis.

MATERIALS AND METHODS

This study was an open labelled comparative trial conducted in accordance with the declaration of Helsinki and was approved by the Ethics committee of Government Medical College, Kozhikode. It was conducted in the outpatient clinic of the Dermatology Department, Government Medical College, Kozhikode, Kerala, India. A total of 60 (n=60) patients were included in this study. Written informed consent was taken from all the subjects. The diagnosis and treatment of Tinea corporis was done with the help of consultant dermatologist.

Patient selection

Inclusion criteria

Tinea corporis is one of the most prevalent dermatophytosis in Kozhikode and the patients suffering from chronic, recurrent and wide spread lesions of tinea corporis were included in the study.

Exclusion criteria

Diabetic and other immunocompromised patients, all mixed infections with candidiasis and patients taking medications for concomitant diseases were excluded.

Study procedure

About 60 patients (both male and female) with dermatophytosis attending outpatient clinic of dermatology department were selected randomly. The description of baseline parameters of patients included in the study is given in table 1. The diagnosis was done by clinical and microscopic examination by mounting skin scrapings in 10% KOH solution.

Table 1: Description of baseline parameters of patients included in the study

| | Oral Fluconazole | Topical Miconazole Nitrate | Topical ketoconazole 2% |
|-----------------------------|------------------|----------------------------|-------------------------|
| Total Number of patients | 30 | 15 | 15 |
| Mean age (Yrs.) | 37 | 32 | 33 |
| Number of Males and Females | 28 M and 02F | All males | All males |

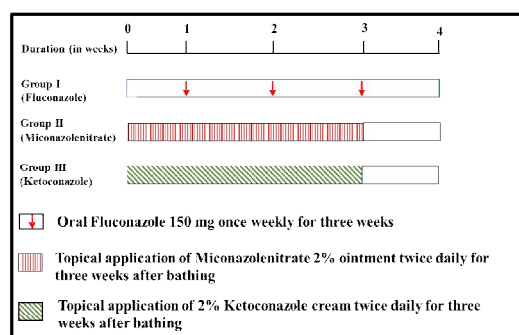


Figure 1: Experimental design

The patients were grouped into three: - Group I consisted of 30 patients and they were treated with oral fluconazole 150mg once weekly for three consecutive weeks. Group II consisted of 15 patient and they were treated after bathing with topical application of Miconazole nitrate 2% ointment twice daily for three consecutive weeks. In group III 15 patients were included. They were treated after bathing with topical application of 2% ketoconazole cream twice daily for three consecutive weeks. There was a regular weekly follow up for four weeks and also after two months.

The clinical end points recorded were reduced itching, reduced erythema and disappearance of inflammatory signs and reappearance of normal skin colour. Clinical cure was also confirmed by microscopic examination of skin scrapings mounted in 10% KOH solution. The adverse effects reported were also recorded. All the medicines for this study were provided to the patient free of cost from the hospital pharmacy. Patient compliance was assessed from history and pill count only.

Definition of clinical end points

- Mycological cure**- Negative KOH preparation
- Clinical cure** - Complete clearing of all signs and symptoms
- Complete cure** - Mycological cure + Clinical cure
- Effective treatment** - Most if not - all of the disease is cleared + Mycological cure

Statistical Analysis

The comparison of efficacy of short term oral fluconazole with topical antifungal imidazoles was done by chi-square test. The cure rate in each group was expressed as percentage. P value of <0.05 was considered significant and <0.01 as highly significant.

RESULTS

All the 30 patients of Tinea Corporis in Group I were cured completely within 3 weeks of oral fluconazole treatment and no relapse reported after two months.

Serious adverse effects were not reported. However, intense itching was noted in 20 patients after one week of therapy with oral fluconazole, but it was reduced in the second week. Mild abdominal discomfort and head ache were also reported (table 2). This shows that oral fluconazole is very effective and safer in Tinea corporis. The overall cure rate in Tinea Corporis with oral fluconazole therapy at the dose of 150mg weekly for 3 weeks was 100%. The P value is <0.01 . 15 patients were studied in group II. Topical miconazole nitrate - 2% cream was applied over the lesions twice daily for three weeks. Out of the 15 patients with Tinea corporis, 9 patients were cured completely within two weeks and no relapse was reported further from these patients. Whereas, relapse was seen in 3 other patients after complete cure. Remaining 3 patients did not show any response to the treatment. The overall cure rate in Tinea Corporis with topical miconazole nitrate therapy was 60%. In group III, fifteen patients were treated with topical application of ketoconazole 2%, twice daily for three weeks. Out of the 15 patients with tinea corporis treated with topical application of ketoconazole, 8 patients were cured within 1 week and no relapse occurred. But 7 patients did not shown any improvement. The overall cure rate in tinea corporis with topical application of ketoconazole therapy was 53%. Figure 2 depicts the assessment of cure rate of tinea corporis to oral fluconazole, topical miconazole nitrate and topical ketoconazole.

Table.2: Response of tinea corporis to the drugs used

| Groups (Drugs) | Results | Adverse effects |
|----------------------------------|---------------|--|
| Group I (Oral Fluconazole) | Complete cure | Head ache, Itching, Abdominal discomfort |
| Group II (Miconazole nitrate 2%) | Satisfactory | Increased itching of the area |
| Group III (Ketoconazole 2%) | Satisfactory | Increased itching of the area |

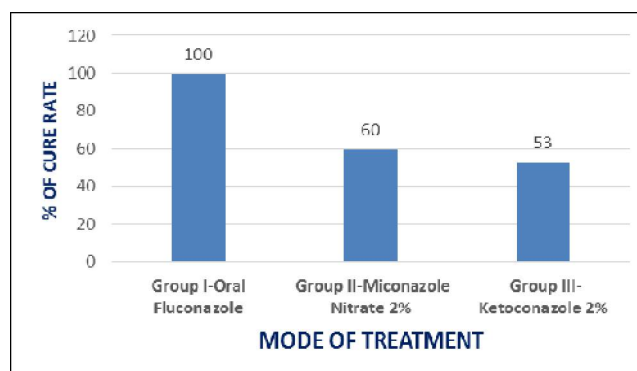


Figure 2: Assessment of cure rate

DISCUSSION

Dermatophytosis, particularly tinea corporis, has been successfully treated with a variety of topical drug formulations once or twice daily for 1 to 6 weeks. The

topical antifungals are usually most effective for localized infections. Oral agents approved for tinea corporis include griseofulvin, ketoconazole, itraconazole and fluconazole. They are used in widespread, chronic

or recurrent conditions¹⁷. All oral agents except fluconazole produce several adverse effects and hepatotoxicity is prominent amongst them¹⁸. Fluconazole is used orally for treatment of tinea versicolor, vaginal and oral candidiasis, short term treatment of dermatophytosis and long term treatment of distal subungual onychomycosis¹⁹. Del Aguila *et al.*, reported that oral doses of 150mg fluconazole once weekly for 3-4 weeks in multicenter open label study on 70 patients in the treatment of tinea pedis produced 77% cure rate²⁰. Stary and Sarnow investigated the efficacy of fluconazole in the treatment of tinea corporis and tinea cruris in a single center open label study. 100 patients studied with same dosing schedule of fluconazole showed 71% cure rate²¹. In a double-blind, parallel group study Faergemann *et al.*, compared fluconazole 150mg once weekly with griseofulvin 500mg once daily for 4-6 weeks in the treatment of tinea corporis or tinea cruris. According to their findings, fluconazole 150mg once weekly for 6 weeks was both clinically and mycologically effective in the treatment of tinea corporis and tinea cruris. The adverse events reported were also less for fluconazole²². In the present study, short term oral fluconazole was compared with 2% ketoconazole cream and Miconazole nitrate 2% ointment in an open label fashion. Fluconazole was found to be effective in the treatment of tinea corporis when compared to ketoconazole and miconazole. The cure rate in the treatment of tinea corporis with oral fluconazole was 100% and no relapse was reported with the treatment. The antifungal activity of fluconazole is accomplished by preventing fungal membrane sterol synthesis through the inhibition of cytochrome P450 (CYP) dependent lanosterol C-14 α -demethylase conversion of lanosterol to ergosterol, resulting in an impairment of fungal cell replication. Even though CYP is present in mammalian cells, fluconazole is highly selective for fungal CYP. Fluconazole is well absorbed orally with extensive bioavailability, and most of the drug is excreted unchanged in the urine; only 11% is excreted as metabolites, while a small percentage is excreted in the feces. The elimination half-life of the drug is about 30 h (range 20–50 h)¹⁶. Once weekly fluconazole at 150mg has the potential advantage of causing less adverse events and interactions. Nausea, head ache, skin rash, vomiting, abdominal pain and diarrhoea are the most common adverse reactions occurring in 1-4% of patients. Hepatocellular dysfunction manifested by elevated LFT is the most common laboratory abnormality²³. In this study the adverse effects observed with fluconazole were only head ache, itching and abdominal discomfort. The reason for mild adverse effects observed in this study

may be due to the short term therapy (3 weeks) of oral fluconazole. In our study, the cure rate observed with miconazole and ketoconazole were 60% and 53% respectively. Relapse was seen when the topical antifungals were used for the treatment of tinea corporis. Miconazole is known to interfere with the synthesis of fungal and bacterial lipid membranes as it restrains the synthesis of ergosterol which results in accumulation of toxic methylated sterol intermediates in membranes and subsequently in fungal cell growth arrests. Another mode of miconazole antifungal action is the generation of reactive oxygen species in susceptible fungi and thereby inducing oxidative damage that kills the fungal cell. Side effects are rare if miconazole is applied topically¹². Ketoconazole also inhibits the fungal cytochrome P450 enzyme systems that is necessary for synthesizing steroids (ergosterol), an essential component of the fungal cell membrane²⁴. The topical antifungals often failed to respond in widespread and chronic lesions. In such situations oral antifungals are being used and found to be effective²⁵. This may be the reason for lower efficacy of topical antifungals especially with ketoconazole in the present study, which showed only 53% cure rate in tinea corporis. Furthermore, intense itching was observed with the application of topical antifungals.

CONCLUSION

Tinea corporis is found to be prevalent in Kozhikode, Kerala and that too in males due to high perspiration, lack of personal hygiene and using high alkaline soaps. Based on the studies reviewed and from the present study, it does appear that oral fluconazole is more effective than other topical antifungal agents for the treatment of tinea corporis.

REFERENCES

1. Choudhary SV, Aghi T, Bisati S. Efficacy and safety of terbinafine hydrochloride 1% cream vs eberconazole nitrate 1% cream in localised tinea corporis and tinea cruris. *Indian Dermatol Online J.* 2014 Apr; 5(2):128-31.
2. Sahoo AK, Mahajan R. Management of tinea corporis, tinea cruris, and tinea pedis: A comprehensive review. *Indian Dermatol Online J.* 2016 Mar Apr; 7(2):77-86.
3. Shivamurthy RP, Reddy SG, Kallappa R, Somashekar SA, Patil D, Patil UN. Comparison of topical antifungal agents sertaconazole and clotrimazole in the treatment of tinea corporis-an observational study. *J Clin Diagn Res.* 2014 Sep; 8(9):HC09-12.
4. Roberts SOB, Mackenzie DWR. Mycology. In: Rook A. Editors. *Text Book of Dermatology*. London: Blackwell, 1979; 767.

5. Powell FC, Muller SA. Kerion of the glabrous skin. *J Am Acad Dermatol.* 1982Oct; 7(4):490-4.
6. Goodman and Gillman. The pharmacological basis of therapeutics. In: Hardman JG, Limbird LE, Molinoff PB, Ruddon RW, Editors. 10thed, New York: Mc Graw – Hill, 2001; 1298- 1311.
7. Banerjee M, Ghosh AK, Basak S, Das KD, Gangopadhyay DN. Comparative evaluation of effectivity and safety of topical amorolfine and clotrimazole in the treatment of tinea corporis. *Indian J Dermatol.* 2011 Nov; 56(6):657-62.
8. Havlickova B, Czaika VA, Friedrich M. Epidemiological trends in skin mycoses worldwide. *Mycoses.* 2008 Sep; 51 Suppl 4:2-15.
9. Calvin OM, Thomas JL. Eczema, Psoriasis, cutaneous infections, acne and other common skin disorders. In: Fauci, Braunwald, Kasper, Hauser, Longo, Jameson, Loscalzo, editors. *Harrison's Principles of Internal Medicine.* 17th ed, Vol 1. New York: McGraw-Hill 2008. p. 318.
10. Suschka S, Fladung B, Merk HF. Clinical comparison of the efficacy and tolerability of once daily Canesten with twice daily Nizoral (clotrimazole 1% cream vs. ketoconazole 2% cream) during a 28-day topical treatment of interdigital tinea pedis. *Mycoses.* 2002 Apr; 45(3-4):91-6.
11. Niewerth M, Korting HC. The use of systemic antimycotics in dermatotherapy. *Eur J Dermatol.* 2000 Mar; 10(2):155-60.
12. Pietschmann S, Hoffmann K, Voget M, Pison U. Synergistic effects of miconazole and polymyxin B on microbial pathogens. *Vet Res Commun.* 2009 Aug; 33(6):489-505.
13. Lee KP, Kim JE, Park WH. Cytoprotective effect of rhamnetin on miconazole-induced H9c2 cell damage. *Nutr Res Pract.* 2015 Dec; 9(6):586-91.
14. Yan Z, Liu X, Liu Y, Han Y, Lin M, Wang W, Guan X, Zhu S, Zhang H, Wang Q, Chou L, Zhu X, Hua H. The Efficacy and Safety of Miconazole Nitrate Mucoadhesive Tablets versus Itraconazole Capsules in the Treatment of Oral Candidiasis: An Open-Label, Randomized, Multicenter Trial. *PLoS One.* 2016 Dec 15; 11(12):e0167880.
15. Shrestha S, Jha AK, Pathak DT, Kharel CB, Basukala SM. Ketoconazole or clotrimazole solution wash as a prophylaxis in management and prevention of fungal infection: a comparative study. *Nepal Med Coll J.* 2013 Mar; 15(1):31-3
16. Egunsola O, Adefurin A, Fakis A, Jacqz-Aigrain E, Choonara I, Sammons H. Safety of fluconazole in paediatrics: a systematic review. *Eur J Clin Pharmacol.* 2013 Jun; 69(6):1211-21.
17. Rand S. Overview: The treatment of dermatophytosis. *J Am Acad Dermatol.* 2000 Nov; 43(5 Suppl):S104-12.
18. Goodman and Gillman. The pharmacological basis of therapeutics. In: Hardman JG, Limbird LE, Molinoff PB, Ruddon RW, Editors. 10thed, New York: Mc Graw – Hill, 2001; 1298- 1311.
19. Bertam G Katzung. Basic and Clinical Pharmacology. Antifungal drugs. 8th Ed, Large Medical Books/ Mc Graw – Hill 814 – 822.
20. Del Aguila R, Gei FM, Robles M, Perera-Ramírez A, Male O. Once-weekly oral doses of fluconazole 150 mg in the treatment of tinea pedis. *Clin Exp Dermatol.* 1992 Nov; 17(6):402-6.
21. Stary A, Sarnow E. Fluconazole in the treatment of tinea corporis and tinea cruris. *Dermatology.* 1998; 196(2):237-41.
22. Faergemann J, Mörk NJ, Haglund A, Odegård T. A multicentre (double-blind) comparative study to assess the safety and efficacy of fluconazole and griseofulvin in the treatment of tinea corporis and tinea cruris. *Br J Dermatol.* 1997 Apr; 136(4):575-7.
23. Tripathi KD. Essentials of Medical Pharmacology, 5th Ed, 2003; 715 – 724.
24. Jeschke MG, Williams FN, Finnerty CC, Rodriguez NA, Kulp GA, Ferrando A, Norbury WB, Suman OE, Kraft R, Branski LK, Al-mousawi AM, Herndon DN. The effect of ketoconazole on post-burn inflammation, hypermetabolism and clinical outcomes. *PLoS One.* 2012; 7(5):e35465.
25. Smith EB. The treatment of dermatophytosis: safety considerations. *J Am Acad Dermatol.* 2000 Nov; 43(5 Suppl):S113-9.

Source of Support: None Declared
Conflict of Interest: None Declared